Interpretación básica de la TC del pulmón - III

Un abordaje desde los patrones pulmonares

Julio 2020

PARTE 3

PATRÓN NODULAR
PATRÓN RETICULAR

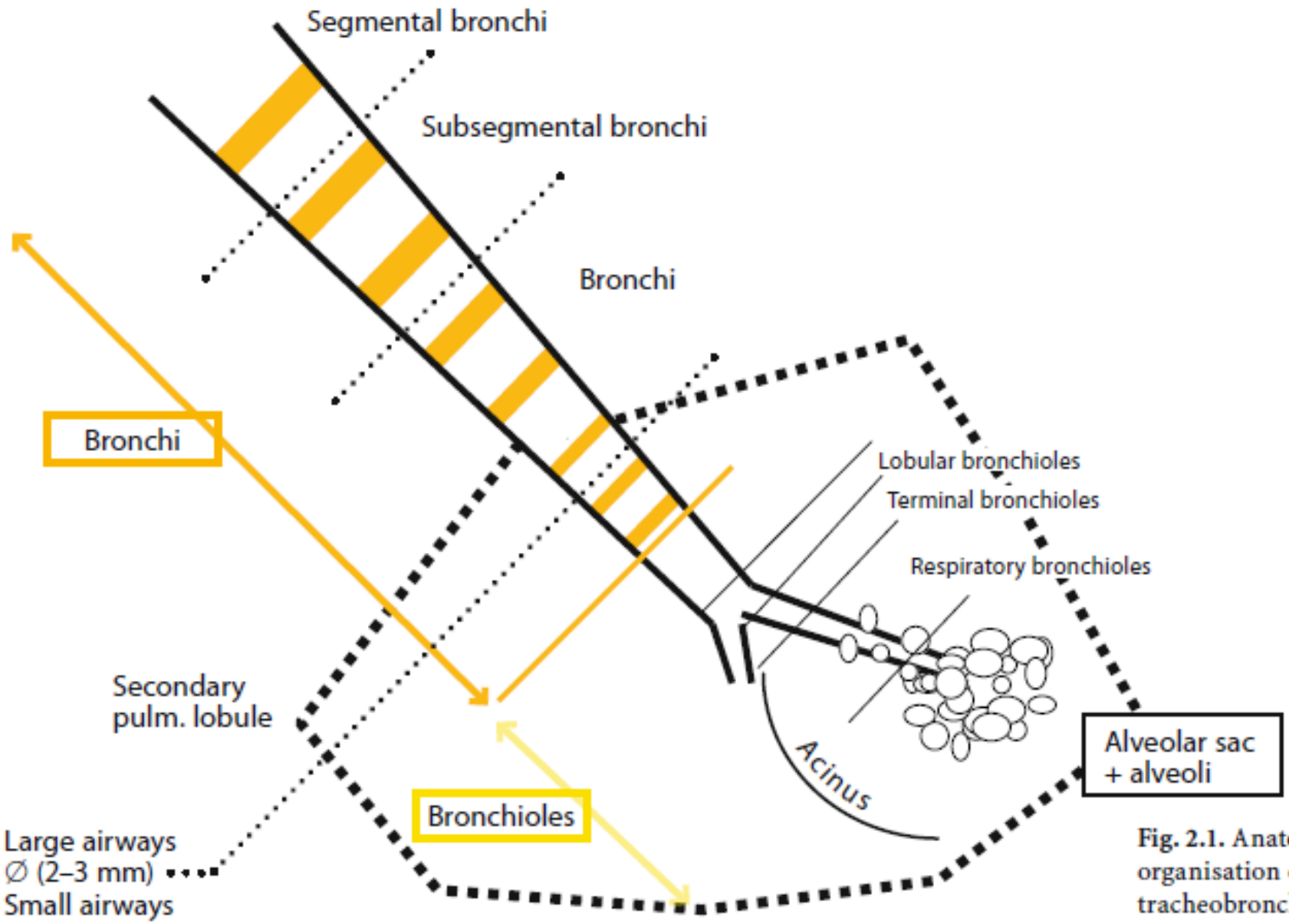

Fig. 2.1. Anatomic organisation of the tracheobronchial tree

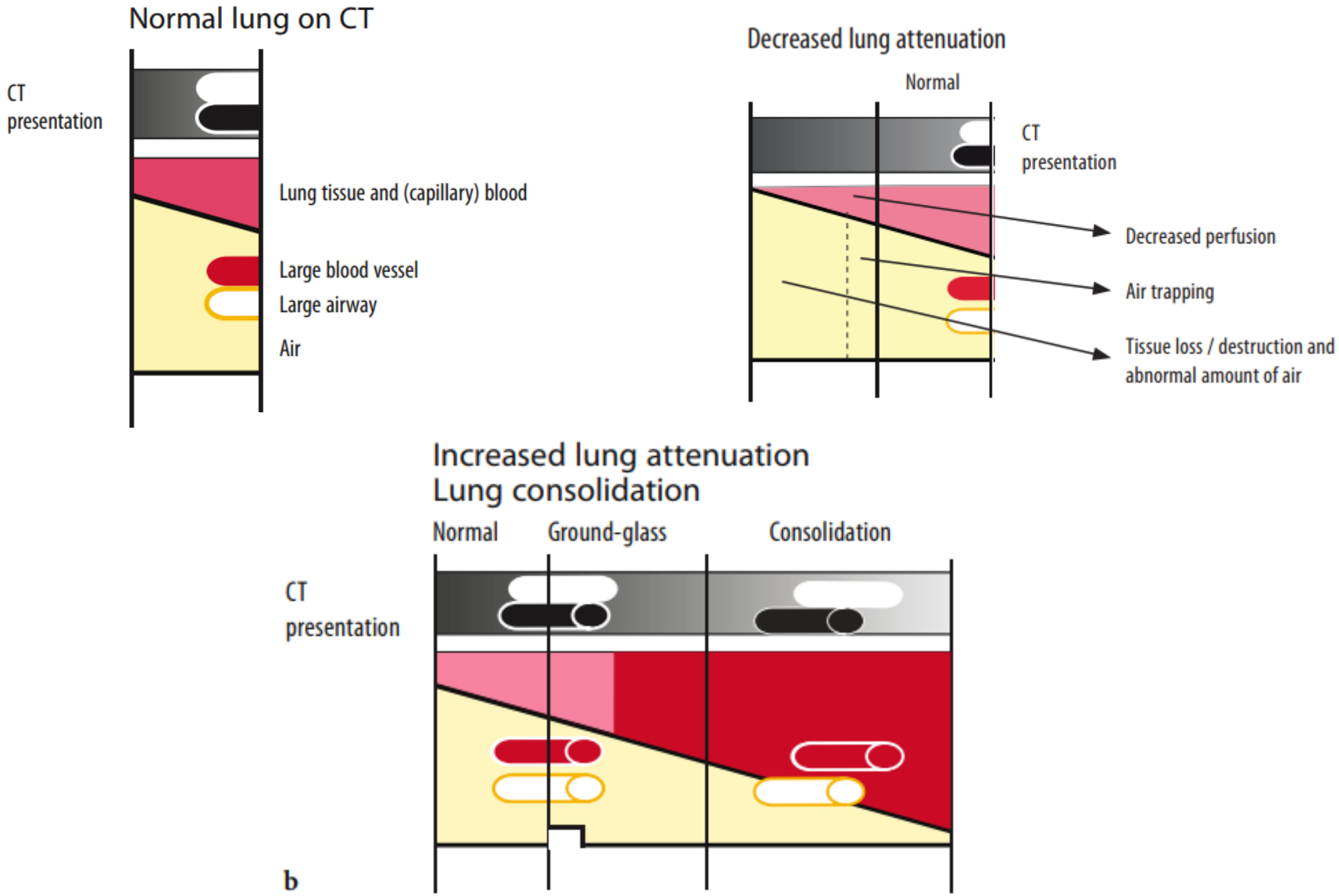
Normal lung on CT
CT presentation
Lung tissue and (capillary) blood
Large blood vessel
Large airway
Air
Decreased lung attenuation
Normal
CT presentation
Decreased perfusion
Air trapping
Tissue loss / destruction and abnormal amount of air
Increased lung attenuation
Lung consolidation
Normal
Ground-glass
Consolidation
CT presentation
b

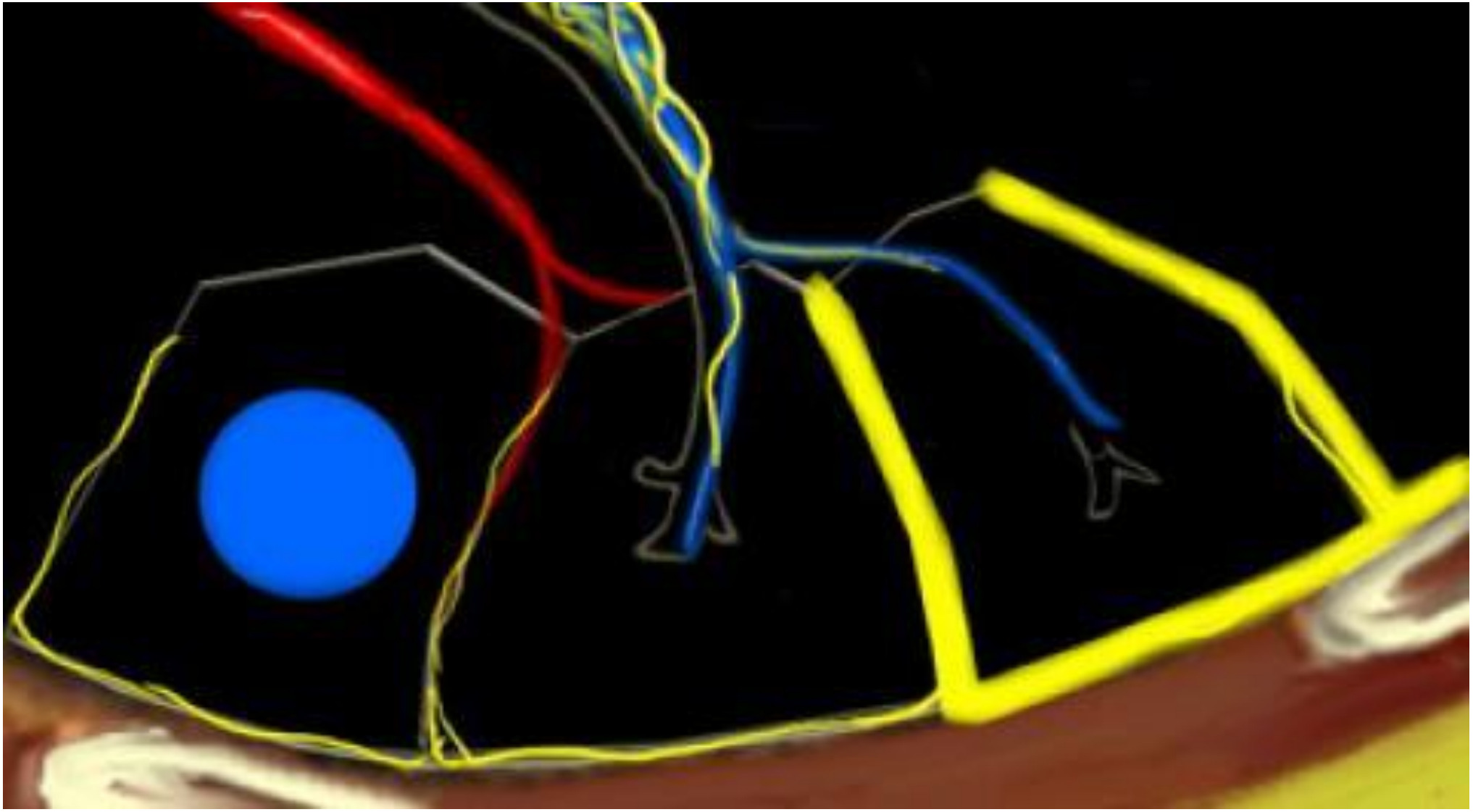

Patrón nodular

Distribución es factor más importante

Más importante que patrón de apariencia

Perilinfática

Espacios pleurales

Septos interlobulares

Intersticio peribroncovascular

Centrilobular

Respeta superficie pleural

Distancia 5 - 10 mm de cisura o pleura

Distribución aleatoria

Cisuras y superficie pleural

No predominancia subpleural (perilinfática)

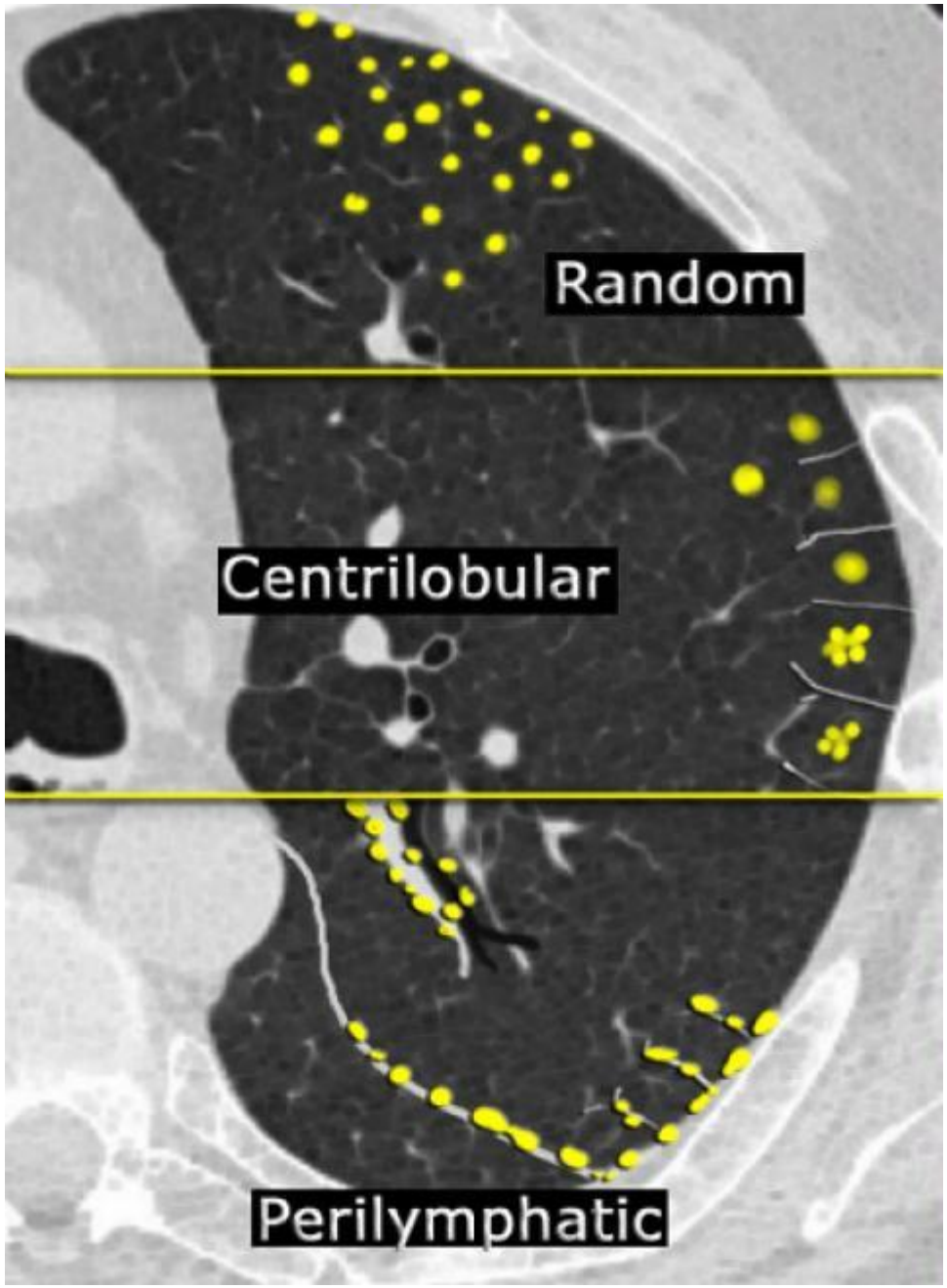

Patrón nodular

- Distribución por vías aéreas –> centrolobulillar a periférico
- Líneas ramificadas centrilobulares (inflamación peribronquiolar)
- Nódulos del espacio aéreo centrilobulillar
- Escarapela de nódulos pequeños
- Patrón de árbol en brote
- Opacificación completa del espacio aéreo del lobulillo secundario

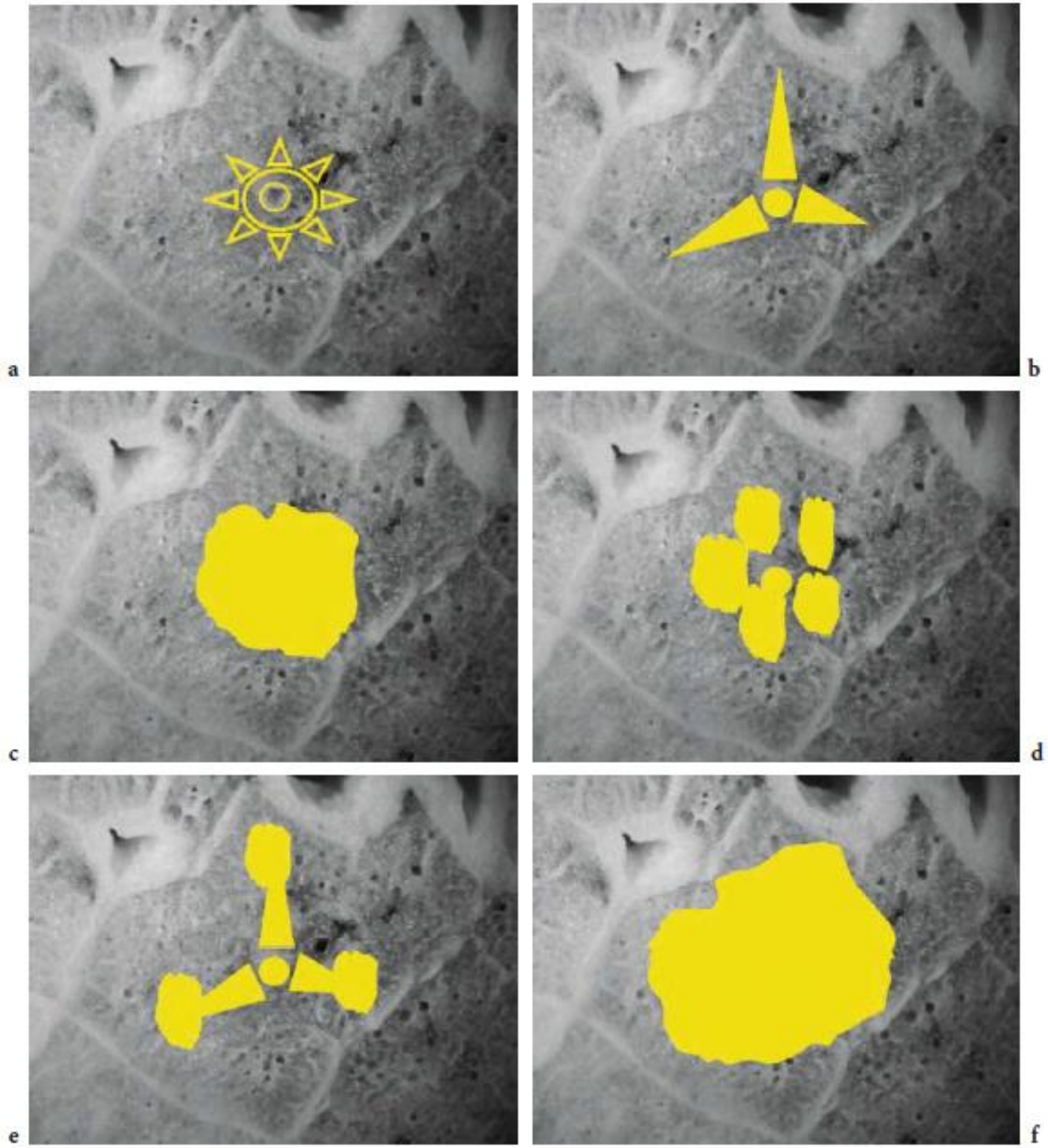

Patrón nodular

- Opacidades múltiples
- Bordes nítidos
- Densidad tejido blando
- Neumoconiosis trabajadores de carbón

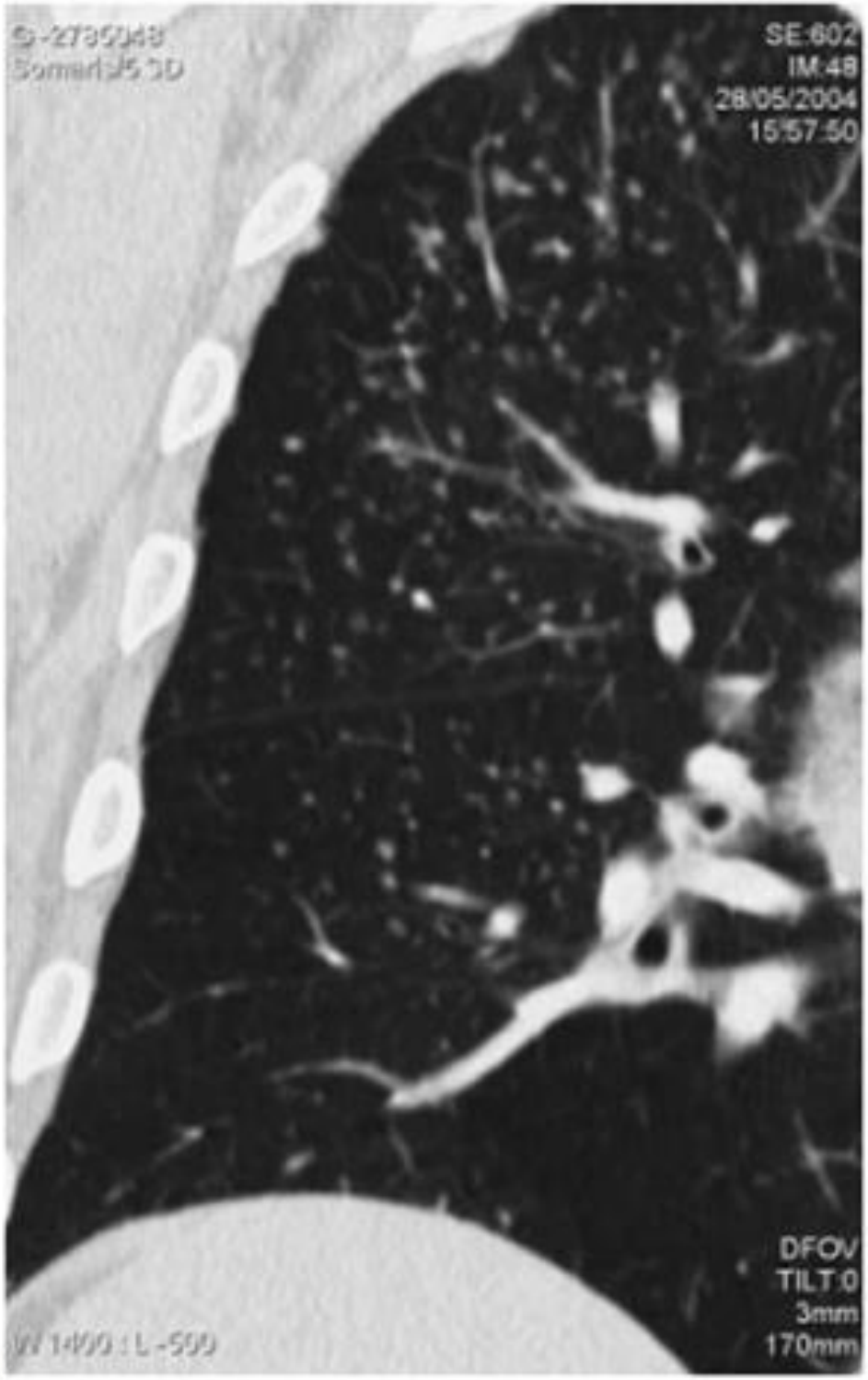

a

Patrón nodular

- Opacidades múltiples
- Densidad de tejido blando
- Otros GGO
- Nmía por micoplasma

b

Patrón nodular

- Múltiples nódulos del espacio aéreo
- Ápice bilateral (+ der)
- Mayormente dens GGO
- Bronquiolitis infecciosa

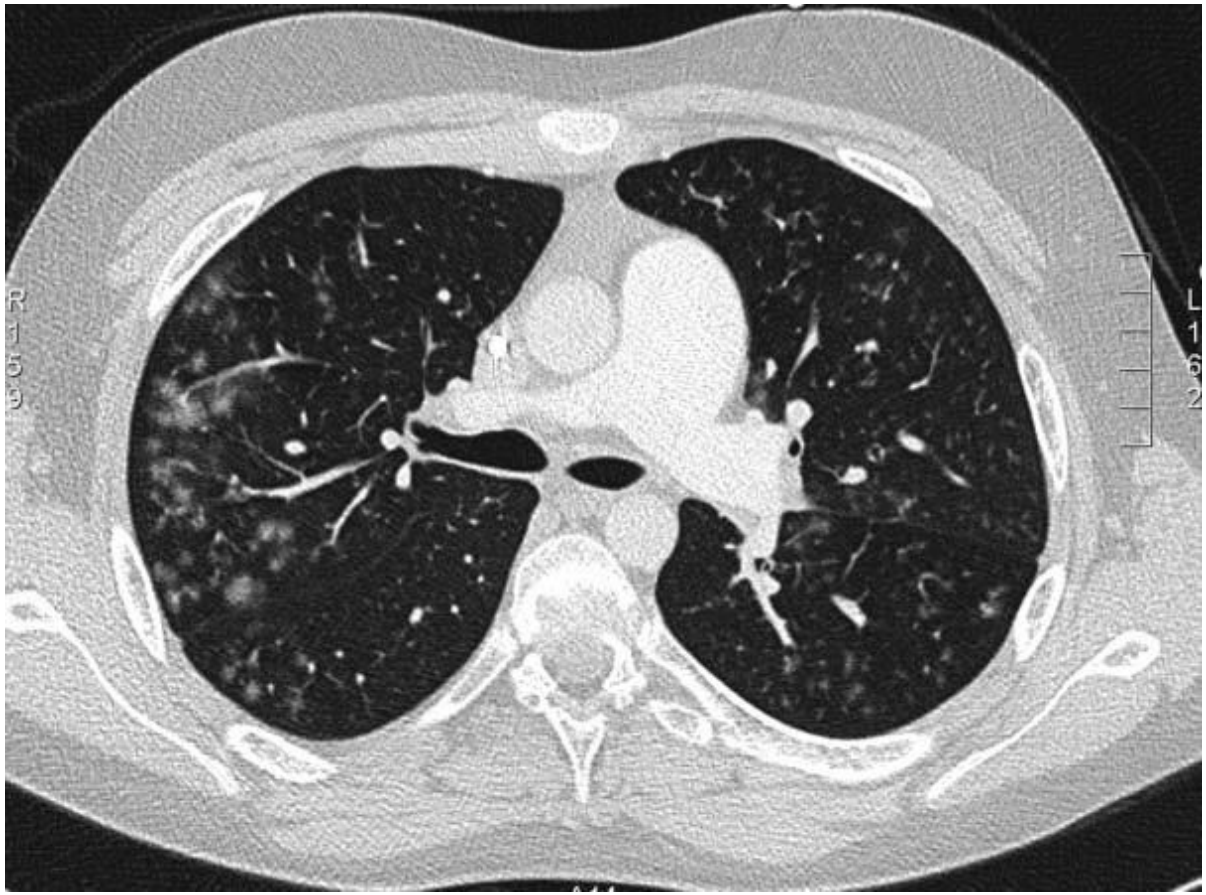

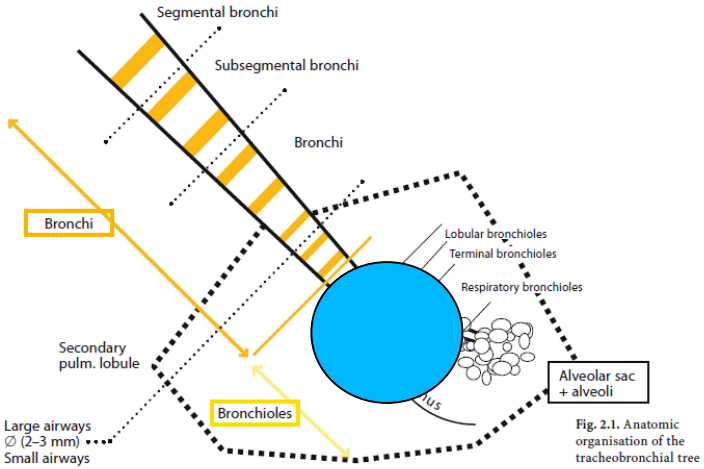

Fig. 2.1. Anatomic organisation of the tracheobronchial tree

Patrón nodular

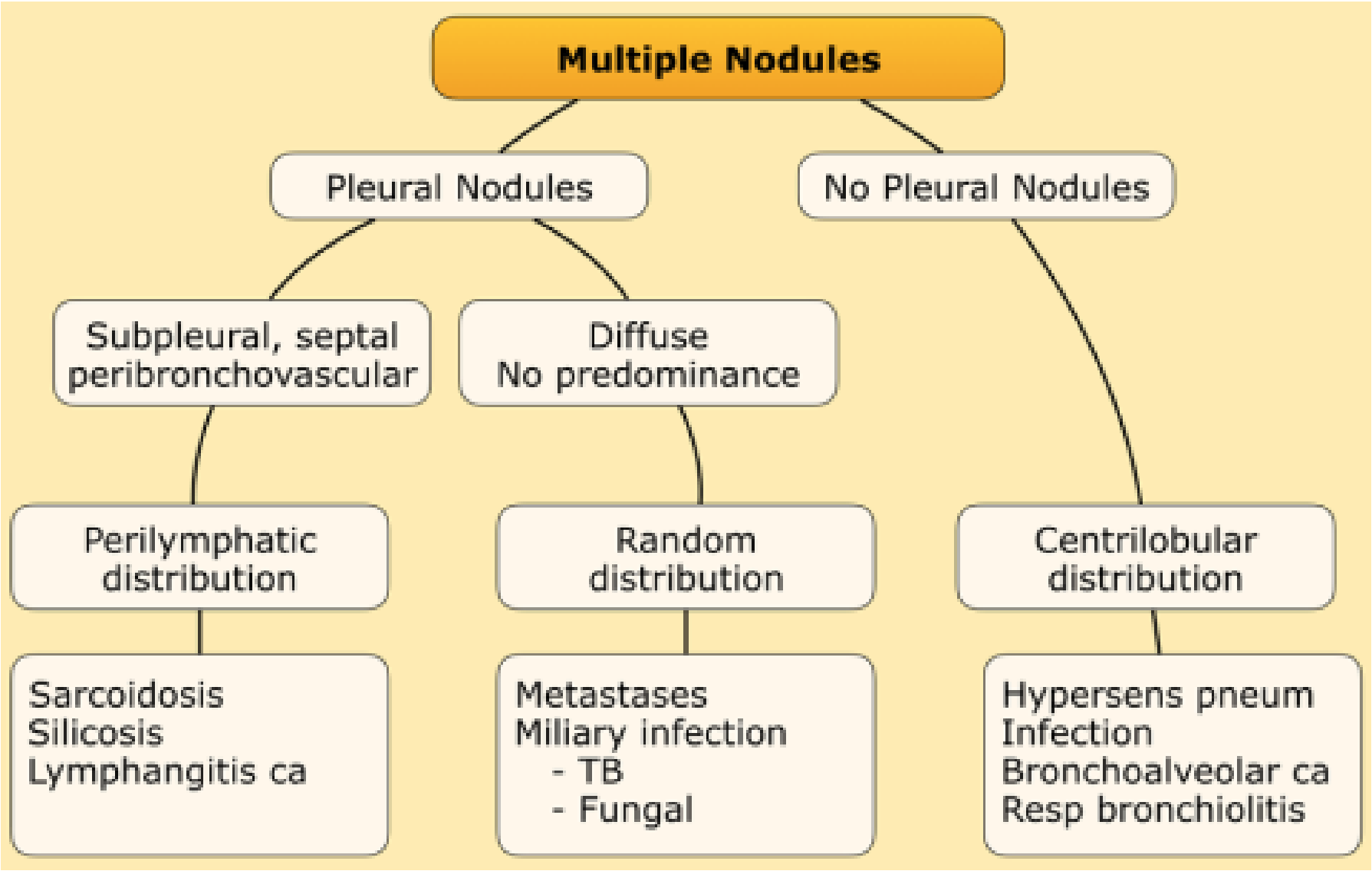

Árbol en brote

Siembra endobronquial

- TB
- Bco-NMIA
- MAV

Aspiración

Retención mucosa

- Aspergillosis broncopulmonar
- Asma

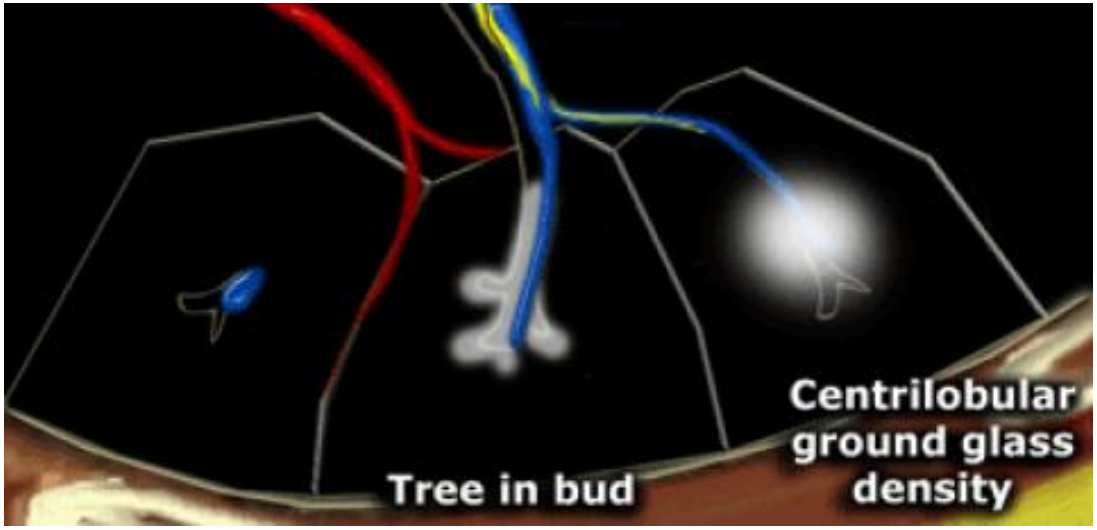

Patrón reticular

Aumento de líneas (cantidad, grosor)

Engrosamiento septos interlobulares

- Líquido
- Infiltración celular
- Enfermedades intersticiales
- Edema pulmonar intersticial
- Carcinomatosis linfangítica

Fibrosis (patrón en panal de abeja)

Patrón reticular

1 TC periférico
2 TC axial
3 TC parenquimatoso

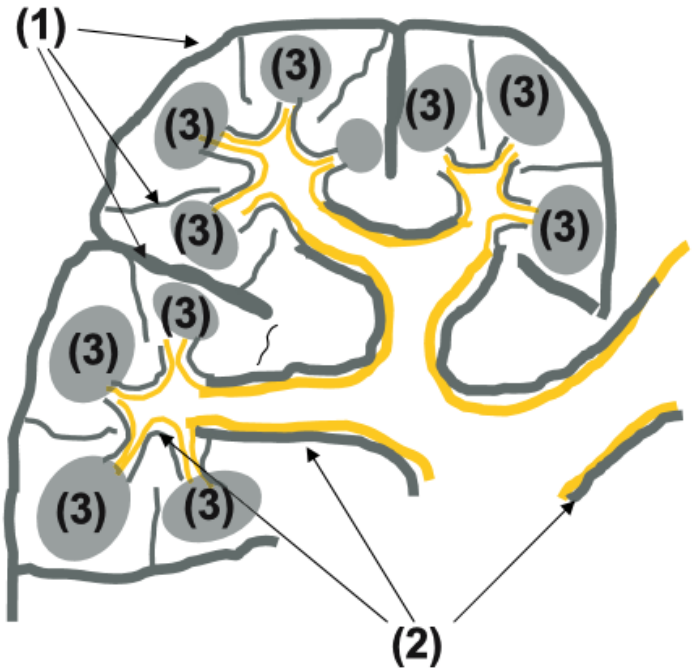

Fig. 2.1. Anatomic organisation of the tracheobronchial tree

Linfangitis carcinomatosa (reticular)

- Engrosamiento septal focal o unilateral (50%)
- Linfadenopatía hiliar 50%
- Historia de malignidad

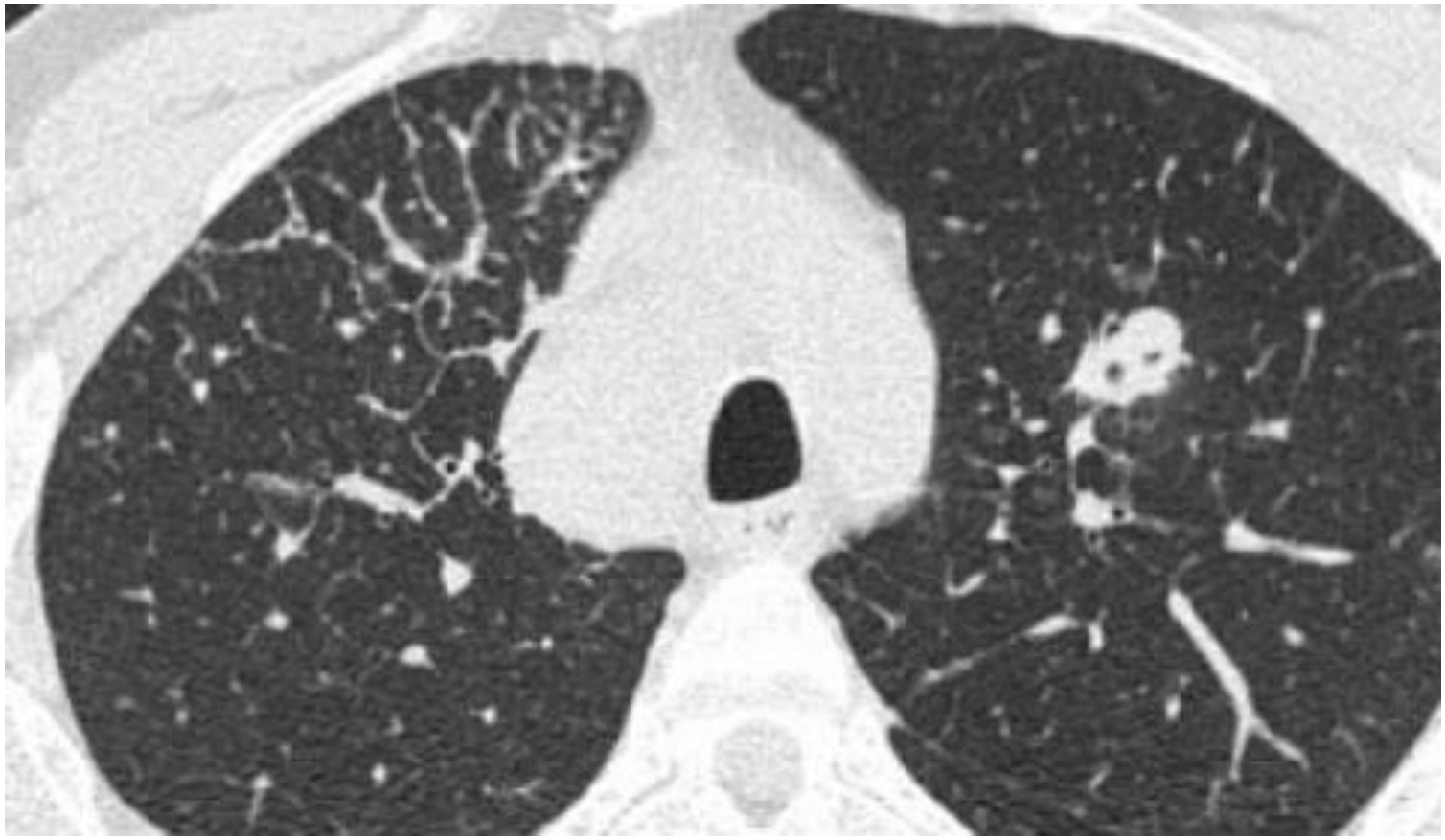

Edema pulmonar cardiogénico (reticular)

- Engrosamiento septal
- Opacidades GGO
- Distribución por gravedad

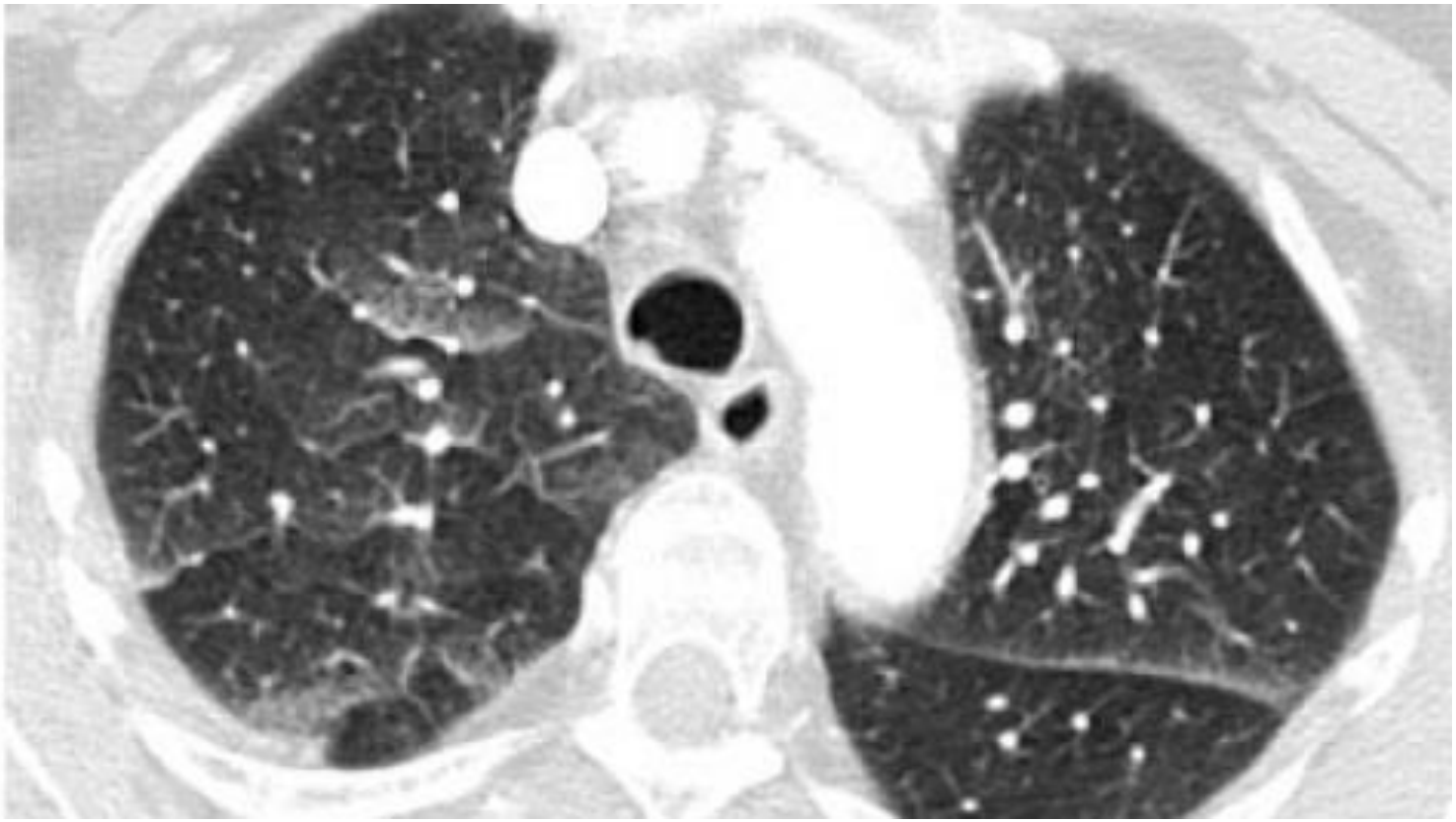

Patrón reticular

Opacidades lineales

Patrón reticular (entrecruzamiento)

Líneas septales (flechas negras)

Líneas intralobulares (cabeza de flecha negra)

Engrosamiento subpleural (flechas blancas)

Intersticio peribroncovascular (cabeza fl. blanca)

1 TC periférico
2 TC axial
3 TC parenqui-
matoso

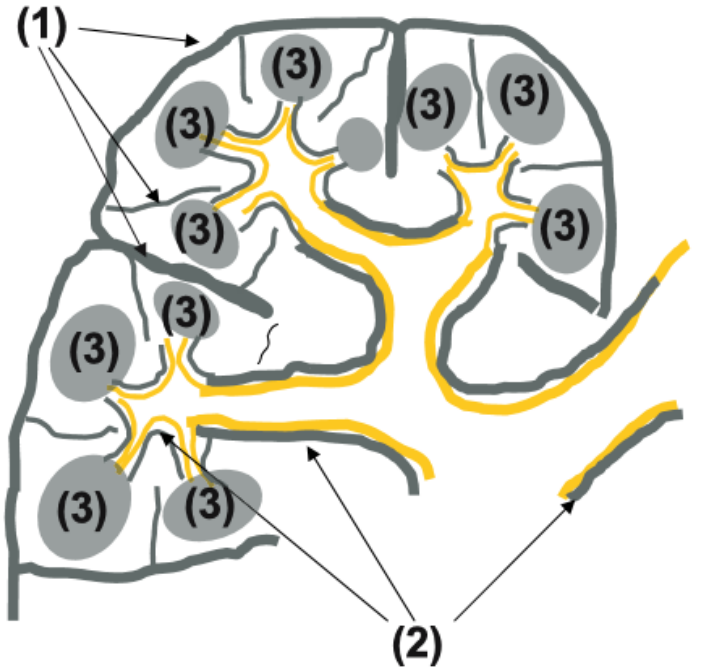

Distribución regional (patrón lineal)

Upper lung versus Lower lung versus Diffuse
Upper: sarcoidosis, silicosis and coal workers' pneumoconiosis, tuberculosis, respiratory bronchiolitis, cystic fibrosis
Lower: oedema, usual interstitial pneumonia (UIP) (idiopathic pulmonary fibrosis (IPF) and disease-associated UIP), asbestosis, nonspecific interstitial pneumonia (NSIP), desquamative interstitial pneumonia (DIP), organising pneumonia, alveolar haemorrhage
Diffuse: chronic hypersensitivity pneumonitis, diffuse pneumonia, lymphangitic spread of tumour, sarcoidosis
Central lung versus peripheral lung
Central: sarcoidosis, silicosis and coal workers' pneumoconiosis, lymphangitic spread of tumour, alveolar proteinosis, large airways disease
Peripheral: usual interstitial pneumonia (UIP) (idiopathic pulmonary fibrosis (IPF) and disease associated UIP), asbestosis, nonspecific interstitial pneumonia (NSIP), chronic eosinophilic pneumonia, organising pneumonia, acute interstitial pneumonia (AIP), desquamative interstitial pneumonia (DIP), hypersensitivity pneumonitis, small airways disease
Posterior versus anterior lung
Posterior: pulmonary oedema, adult respiratory distress syndrome (ARDS), usual interstitial pneumonia (UIP) (idiopathic pulmonary fibrosis (IPF) and disease-associated UIP), asbestosis, nonspecific interstitial pneumonia (NSIP), silicosis and coal workers' pneumoconiosis, sarcoidosis, chronic hypersensitivity pneumonitis
Anterior: post-adult respiratory distress (ARDS) fibrosis
Can be unilateral or asymmetric
Pneumonia, lymphangitic spread of tumour, sarcoidosis

Bibliografía

Verschakelen JA, De Wever W. Computed Tomography of the Lung: A Pattern Approach. Springer-Verlag, Berlin Heidelberg, 2007.

Smithuis R, Van Delden O, Schaefer-Prokop C. HRCT: Basic Interpretation. Radiology Department of the Rijnland Hospital, Leiderdorp and the Academical Medical Centre, Amsterdam, los Países Bajos. Publicado en línea el 24 de diciembre del 2006. Disponible en: https://radiologyassistant.nl/chest/hrct/basic-interpretation