Subfertility: What the Radiologist Needs to Know[1]

Saranya Vickramarajah, BSc, MBBS
Victoria Stewart, BMBS, MRCP, FRCR
Katherine van Ree, MBBS, MRCP, FRCR
Anne P. Hemingway, MBBS, FRCR
Mary E. Crofton, MBBS, FRCR
Nishat Bharwani, MBBS, MRCP, FRCR

Abbreviations: FOV = field of view, HSG = hysterosalpingography

RadioGraphics 2017; 37:1587–1602

https://doi.org/10.1148/rg.2017170053

Content Codes: GU OB US

[1]From the Department of Radiology, St Mary's Hospital, 3rd Floor QEQM Building, London W2 1NY, England; Imperial College Healthcare NHS Trust, London, England (N.B.); and Department of Surgery and Cancer, Faculty of Medicine, Imperial College London, London, England (N.B.). Recipient of a Certificate of Merit award for an education exhibit at the 2016 RSNA Annual Meeting. Received March 12, 2017; revision requested May 8 and received June 18; accepted June 27. For this journal-based SA-CME activity, the authors, editor, and reviewers have disclosed no relevant relationships. **Address correspondence to** N.B. (e-mail: *nishat.bharwani@nhs.net*).

©RSNA, 2017

SUBFERTILIDAD:
LO QUE NECESITA SABER EL RADIÓLOGO

- **INTRO**
  - SUBFERTILIDAD
  - PREVALENCIA
  - INICIO DE MATERNIDAD 1973 - 2013
  - INFERTILIDAD > 1 AÑO
  - ROL DXIM
- **MODALIDADES DE IMÁGENES**
  - ECO
  - HS - ECO CTE
  - HSG
  - MRI
- **CAUSAS**
  - **FERTILIDAD ONCOLOGÍA**
    - TAMIZAJE
    - CVX
    - PREMENO-PAUSIA
    - MRI
    - EM
  - **CONGÉNITAS**
    - **CAVIDAD UTERINA DIVIDIDA**
      - SEPTADO
      - BICORNE
      - DIDELFO
    - MRKH
    - UNICORNE
  - **ADQUIRIDAS**
    - SOP
    - MIOMAS
    - PÓLIPOS
    - EM
    - SME ASH
    - OCL TUB
    - SIN
- **CONCLUSIÓN**
  - MÉDICO
  - QUIRÚRGICO

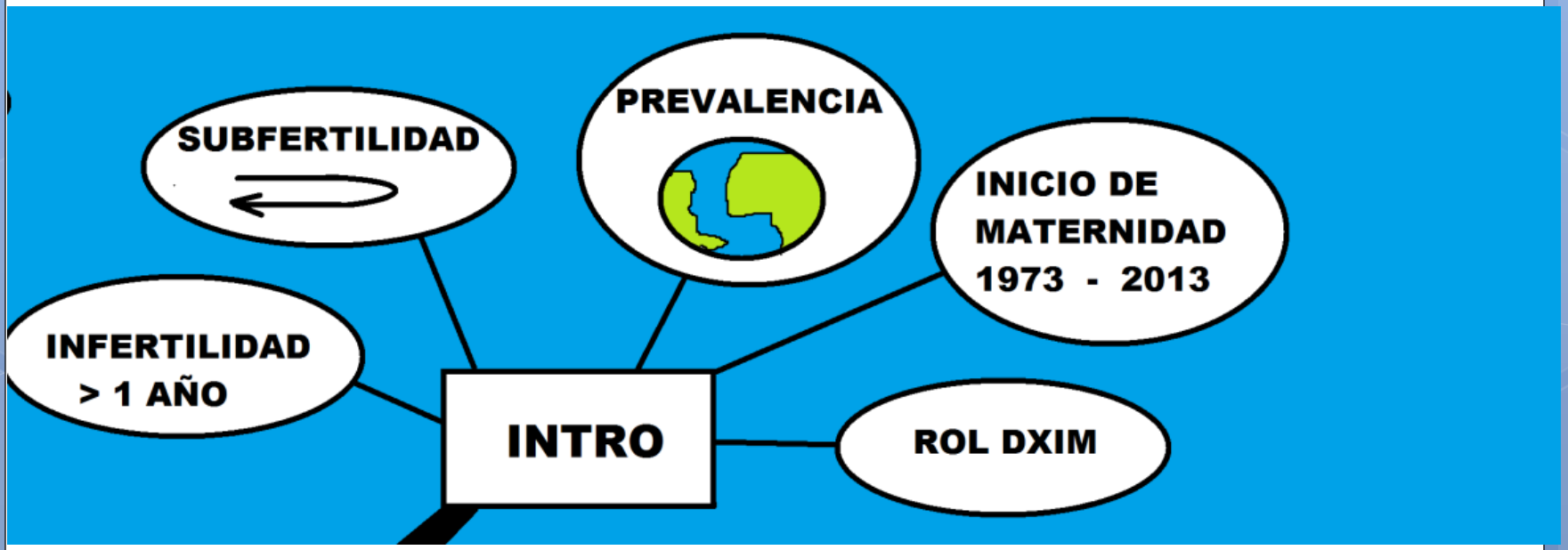
SUBFERTILIDAD
PREVALENCIA
INICIO DE MATERNIDAD 1973 - 2013
INFERTILIDAD > 1 AÑO
INTRO
ROL DXIM

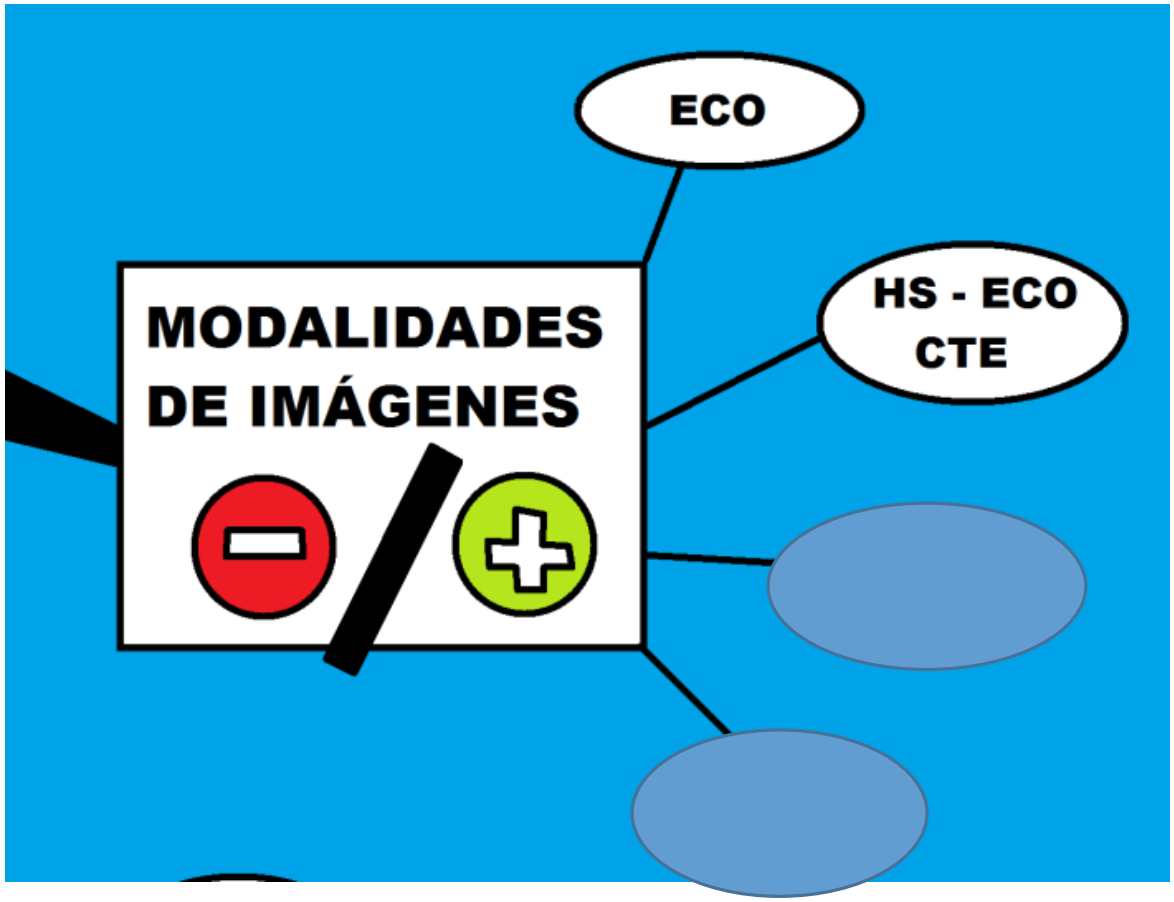
MODALIDADES DE IMÁGENES
ECO
HS - ECO CTE

FIGURA 1

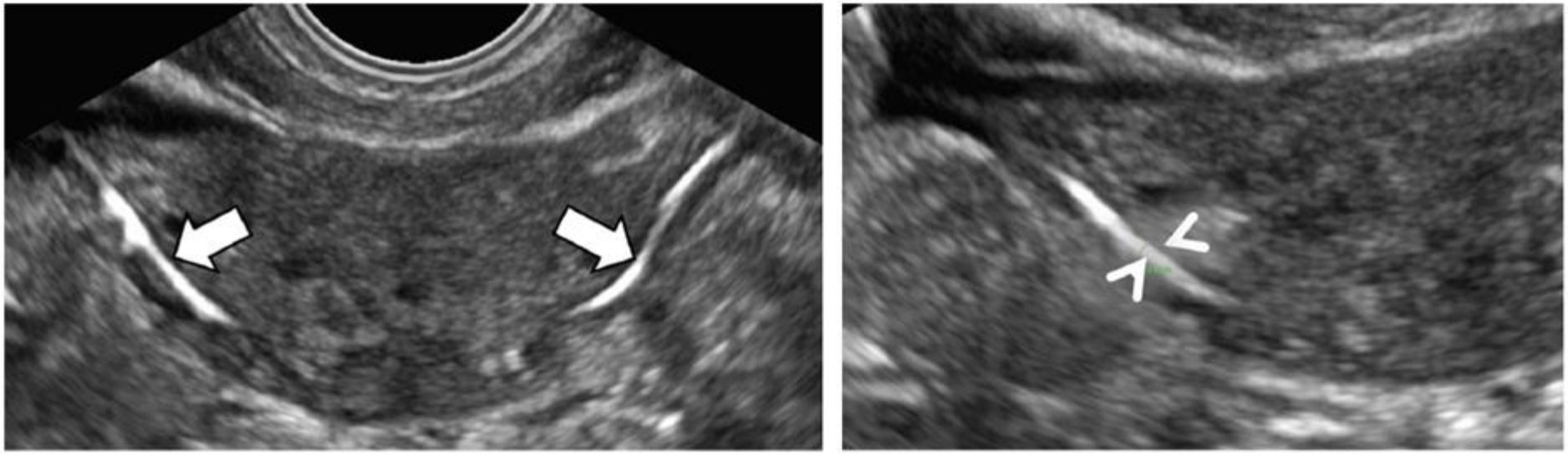

a. b.

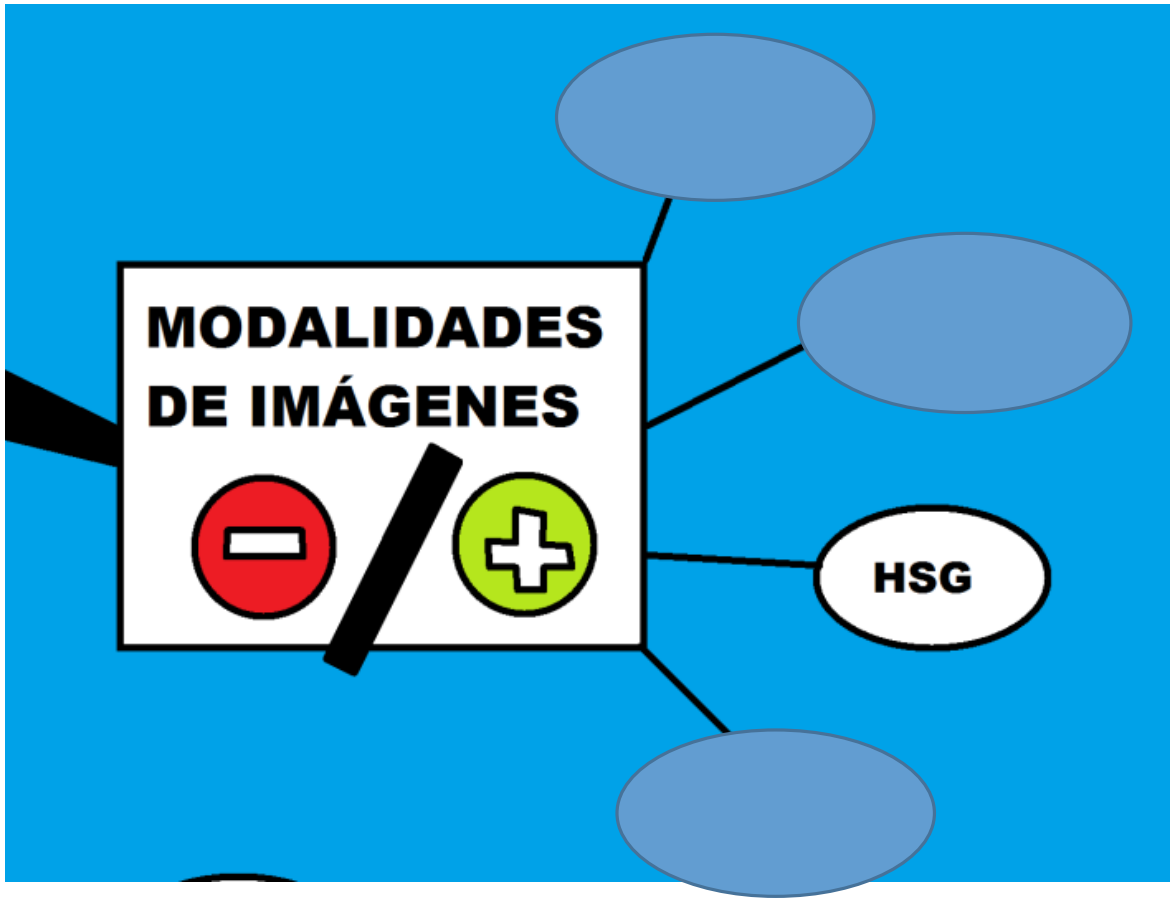
MODALIDADES
DE IMÁGENES
HSG

FIGURA 2

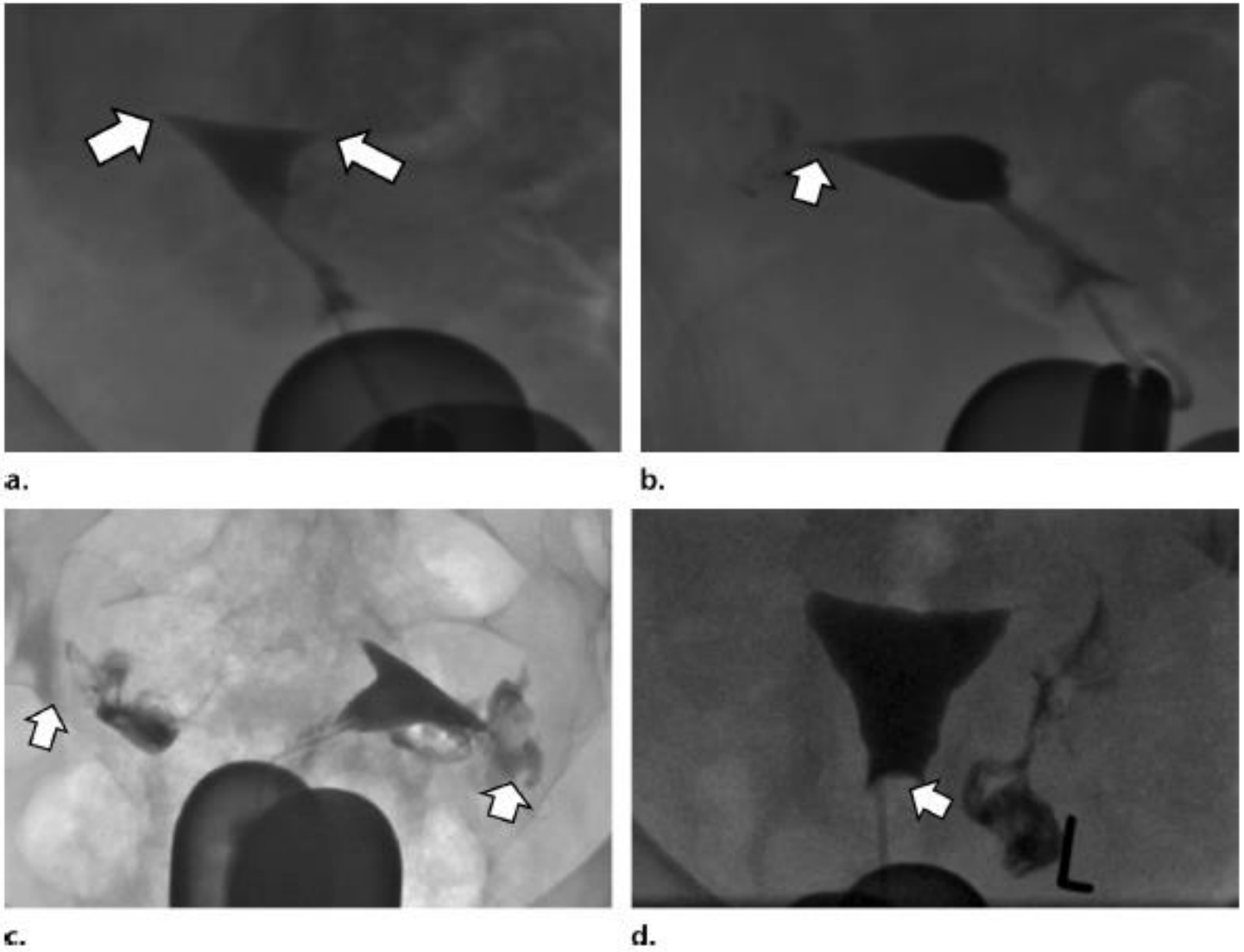

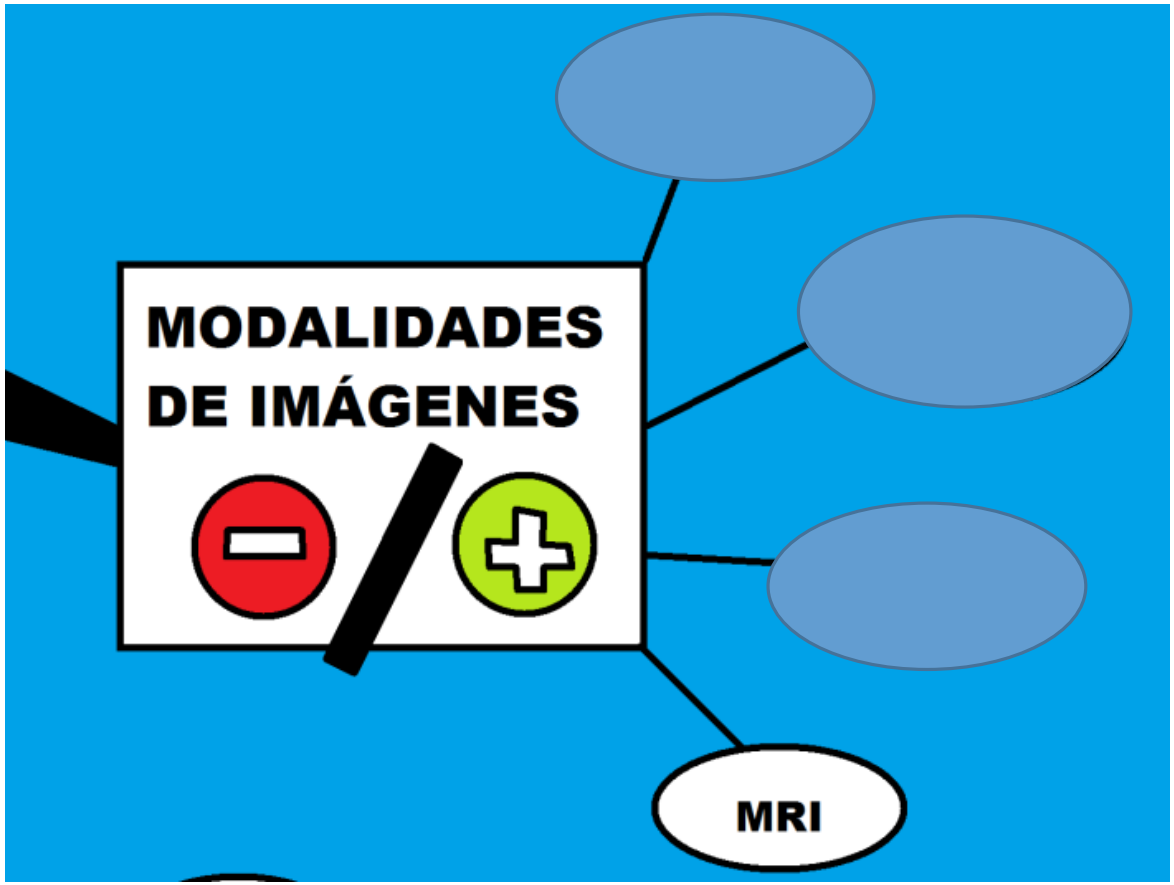
MODALIDADES
DE IMÁGENES
MRI

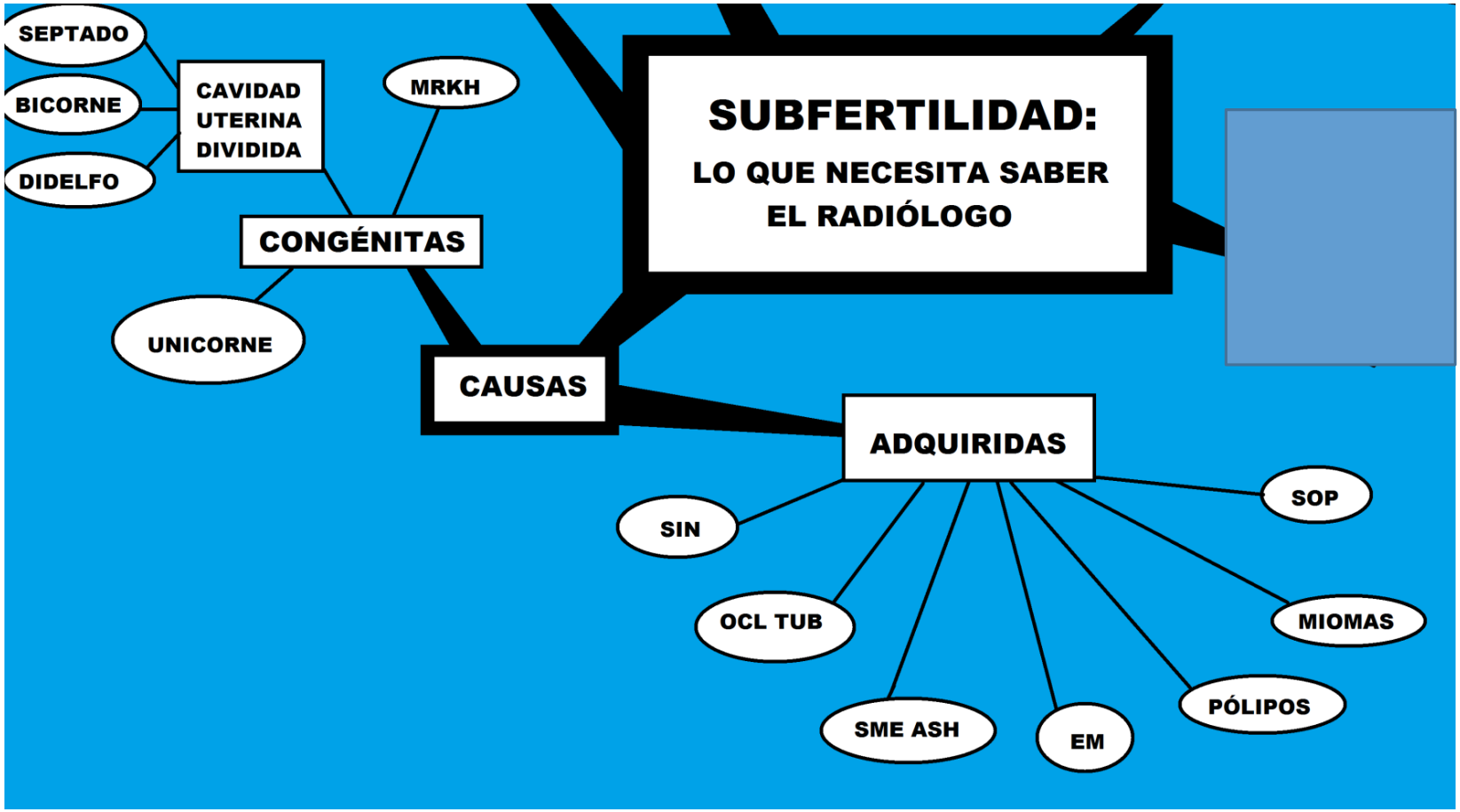
SUBFERTILIDAD:
LO QUE NECESITA SABER EL RADIÓLOGO
CAUSAS
CONGÉNITAS
CAVIDAD UTERINA DIVIDIDA
SEPTADO
BICORNE
DIDELFO
MRKH
UNICORNE
ADQUIRIDAS
SIN
OCL TUB
SME ASH
EM
PÓLIPOS
MIOMAS
SOP

Table 1: Congenital and Acquired Causes of Subfertility

Congenital causes
Uterine developmental anomalies, müllerian duct anomalies
Ovarian aplasia or hypoplasia
Tubal structural abnormalities (rare)
Genetic: Klinefelter syndrome, Turner syndrome
Acquired causes
Intrauterine adhesions (infectious or noninfectious)
Fibroids or polyps
Adenomyosis or endometriosis
Tubal disease
Radiation therapy or chemotherapy (systemic or endocrine)

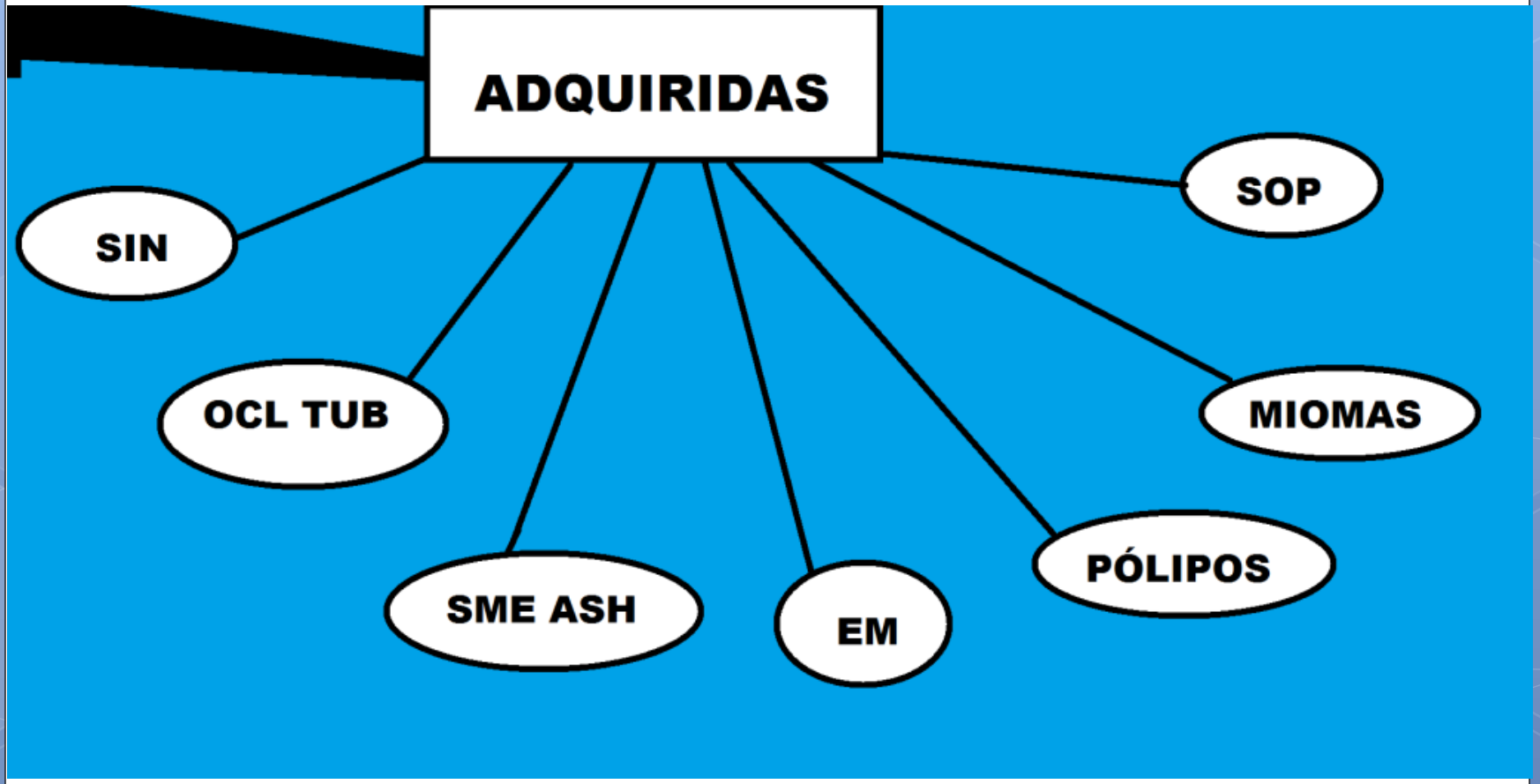
ADQUIRIDAS
SIN
OCL TUB
SME ASH
EM
PÓLIPOS
MIOMAS
SOP

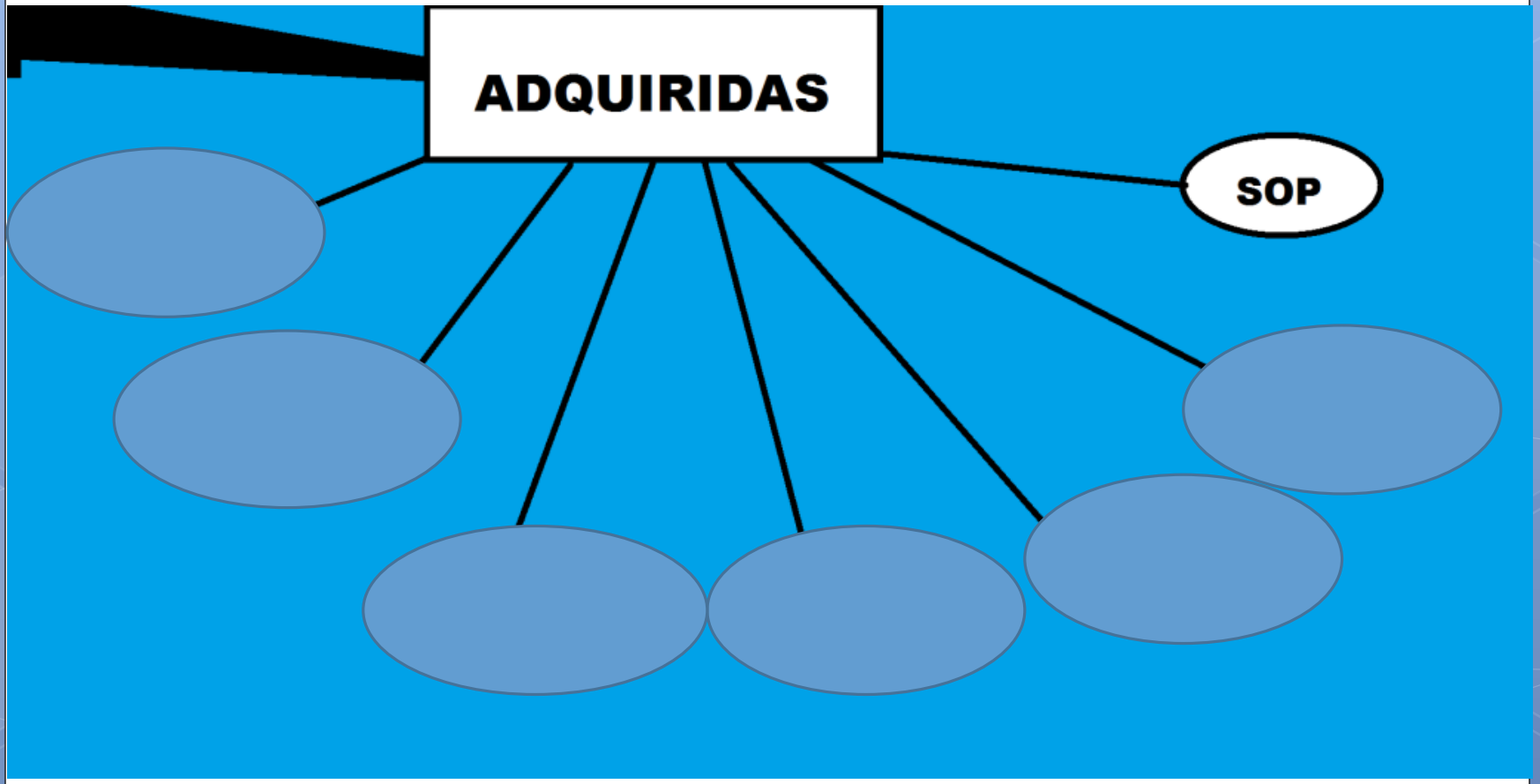
ADQUIRIDAS
SOP

Table 2: Criteria for Defining PCOS

Rotterdam diagnostic criteria (2003)*
Chemical and/or biochemical hyperandrogenism
Oligomenorrhea or oligo-ovulation
Polycystic ovaries at US: ≥12 cysts with diameters of 2–9 mm or increased ovarian volume (≥10 mL)
Dewailly et al 2011 (14)
Substitute follicles per ovary with antimüllerian hormone level > 35 pmol/L

*Two criteria out of three are needed for diagnosis of PCOS.

FIGURA 3

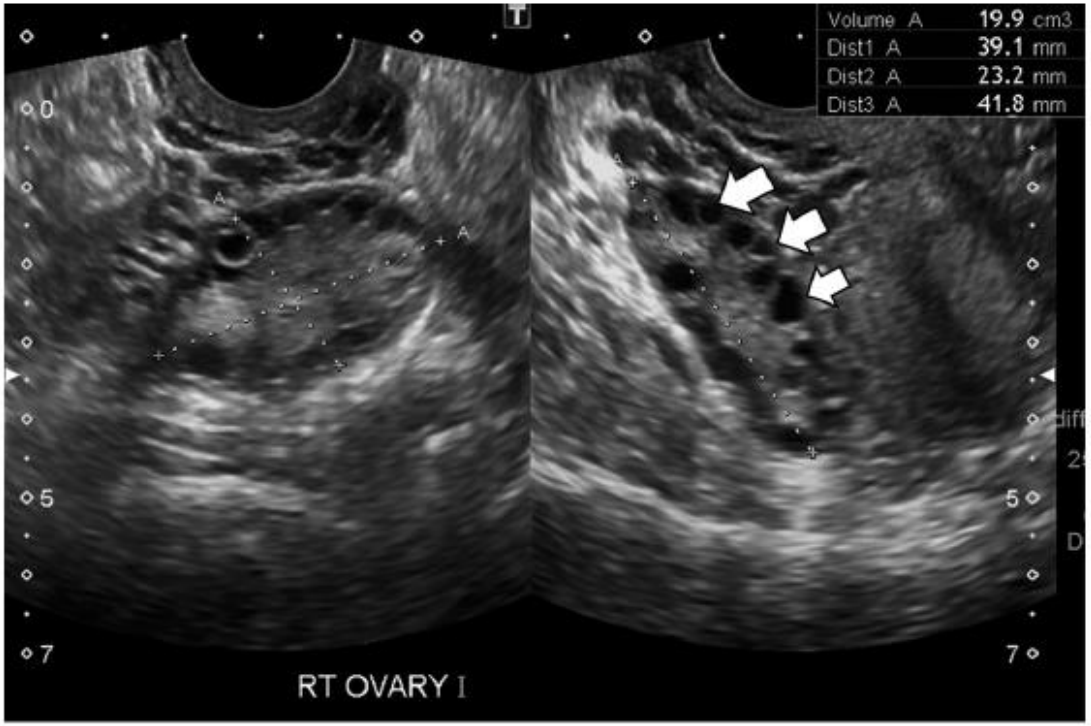
Volume A 19.9 cm3
Dist1 A 39.1 mm
Dist2 A 23.2 mm
Dist3 A 41.8 mm
RT OVARY I

a.

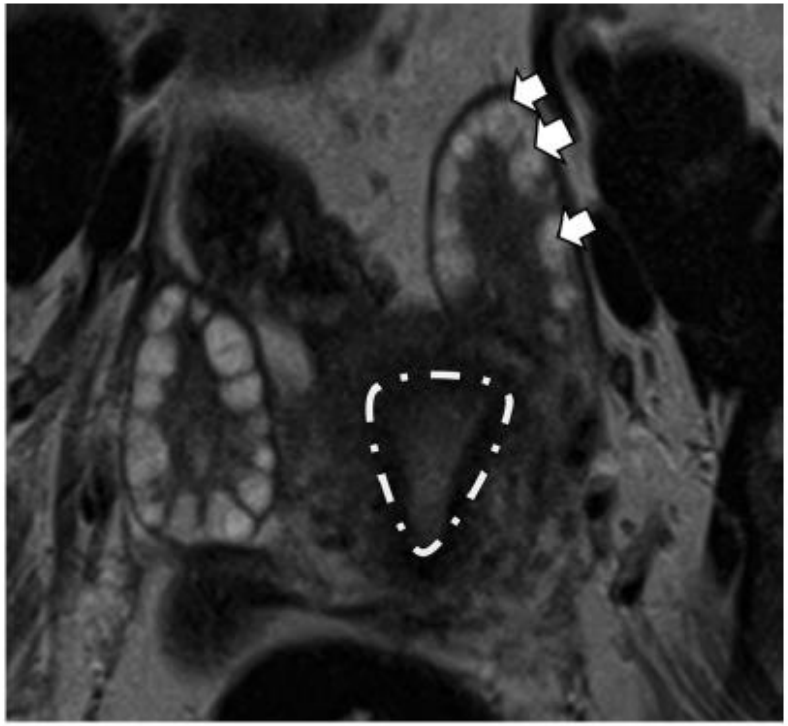

b.

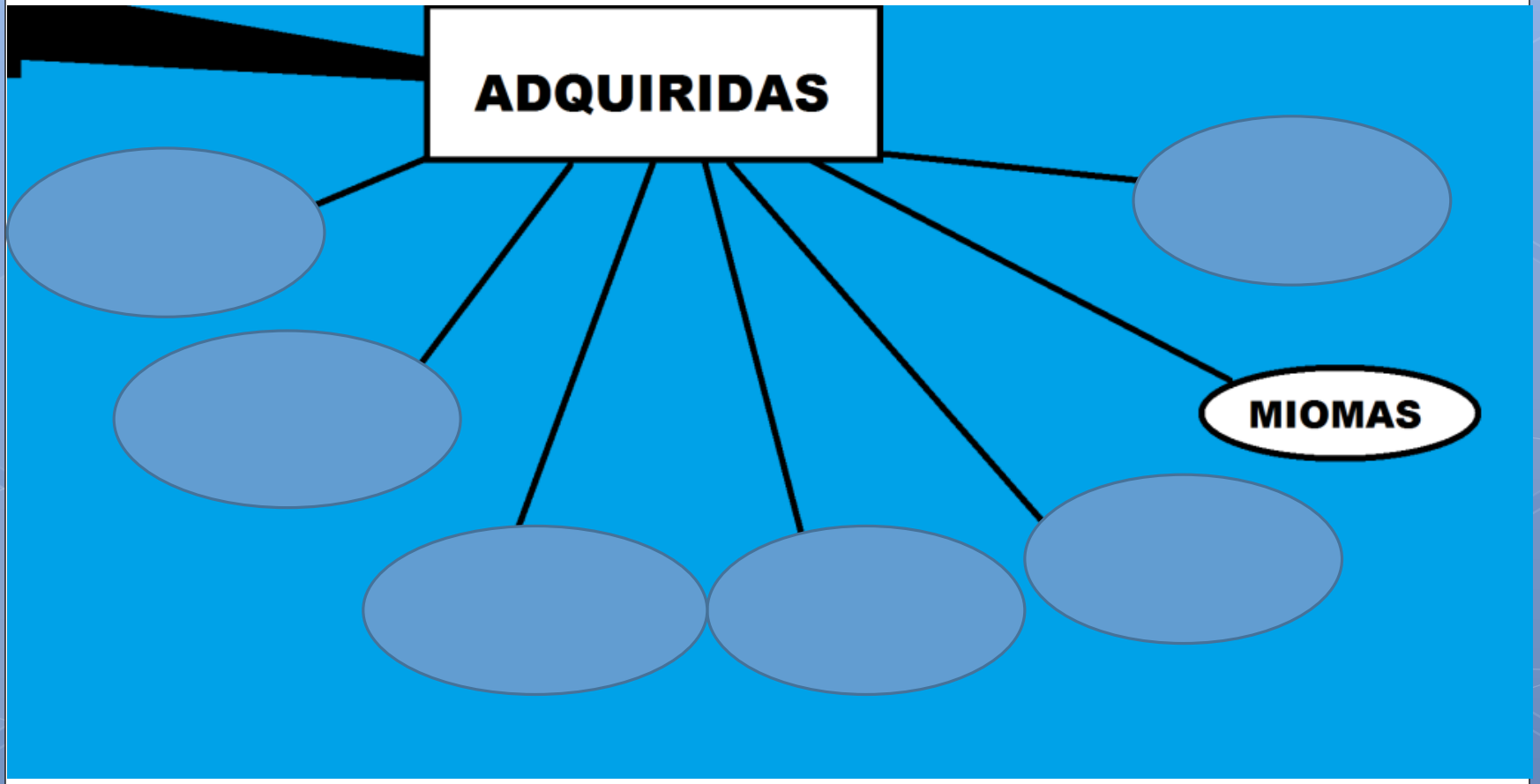
ADQUIRIDAS
MIOMAS

FIGURA 4

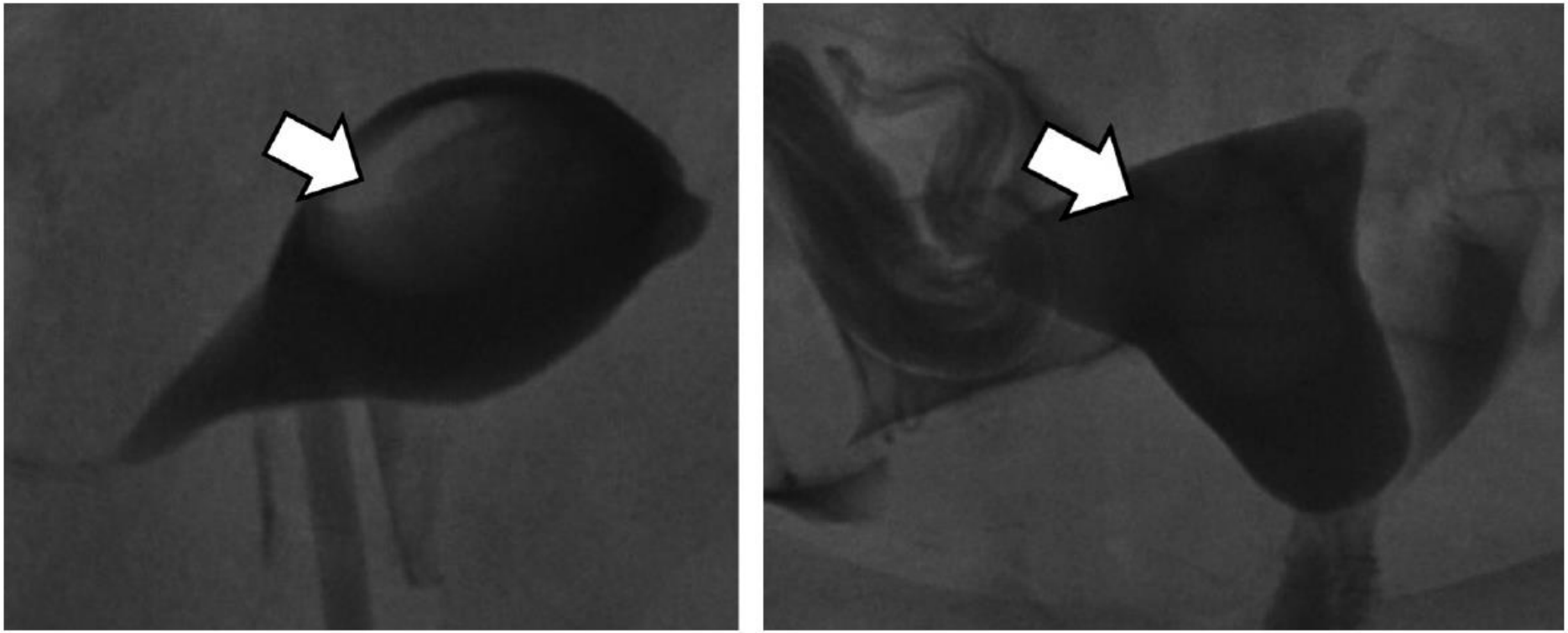

a. b.

FIGURA 5

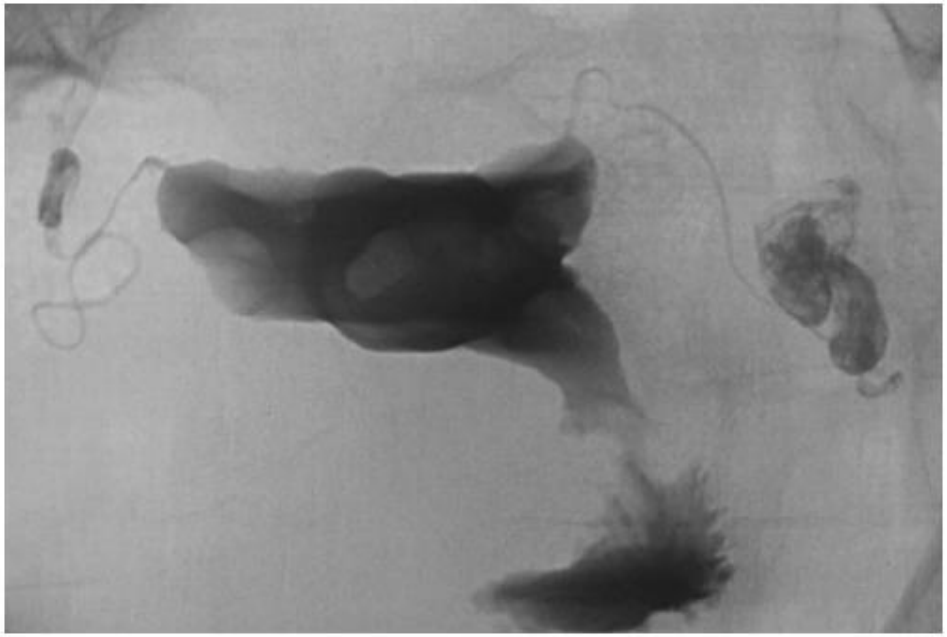

a.

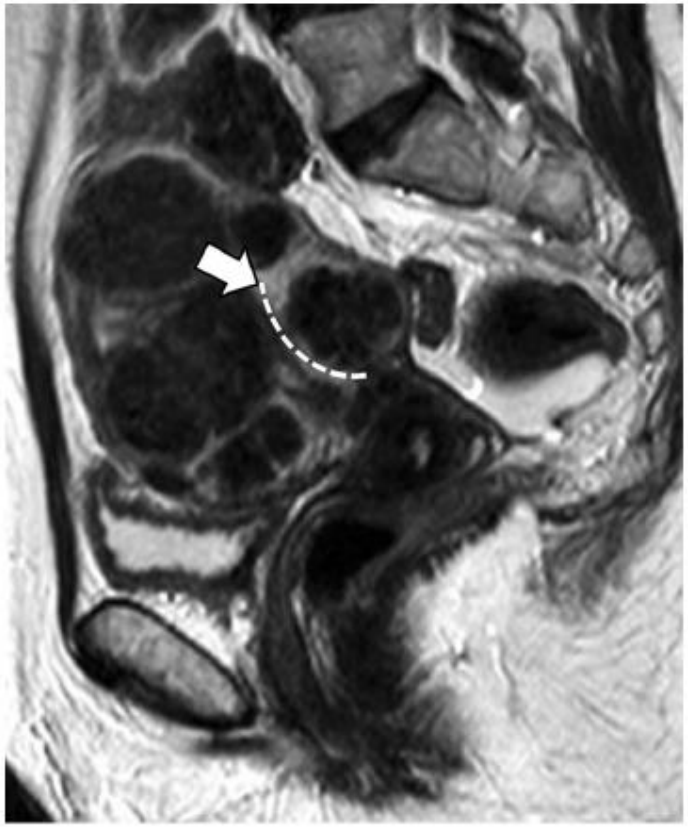

b.

FIGURA 6

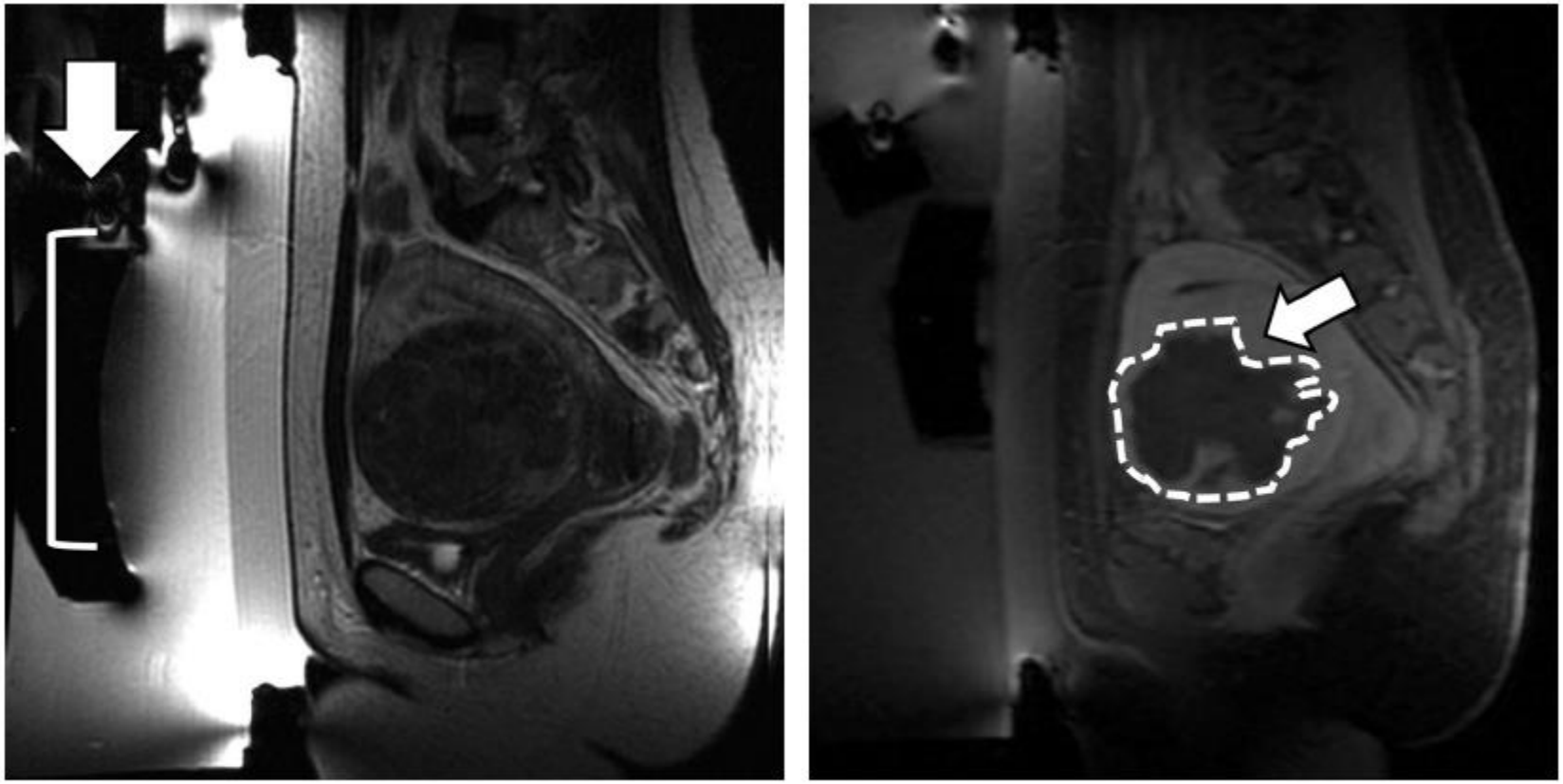

a. b.

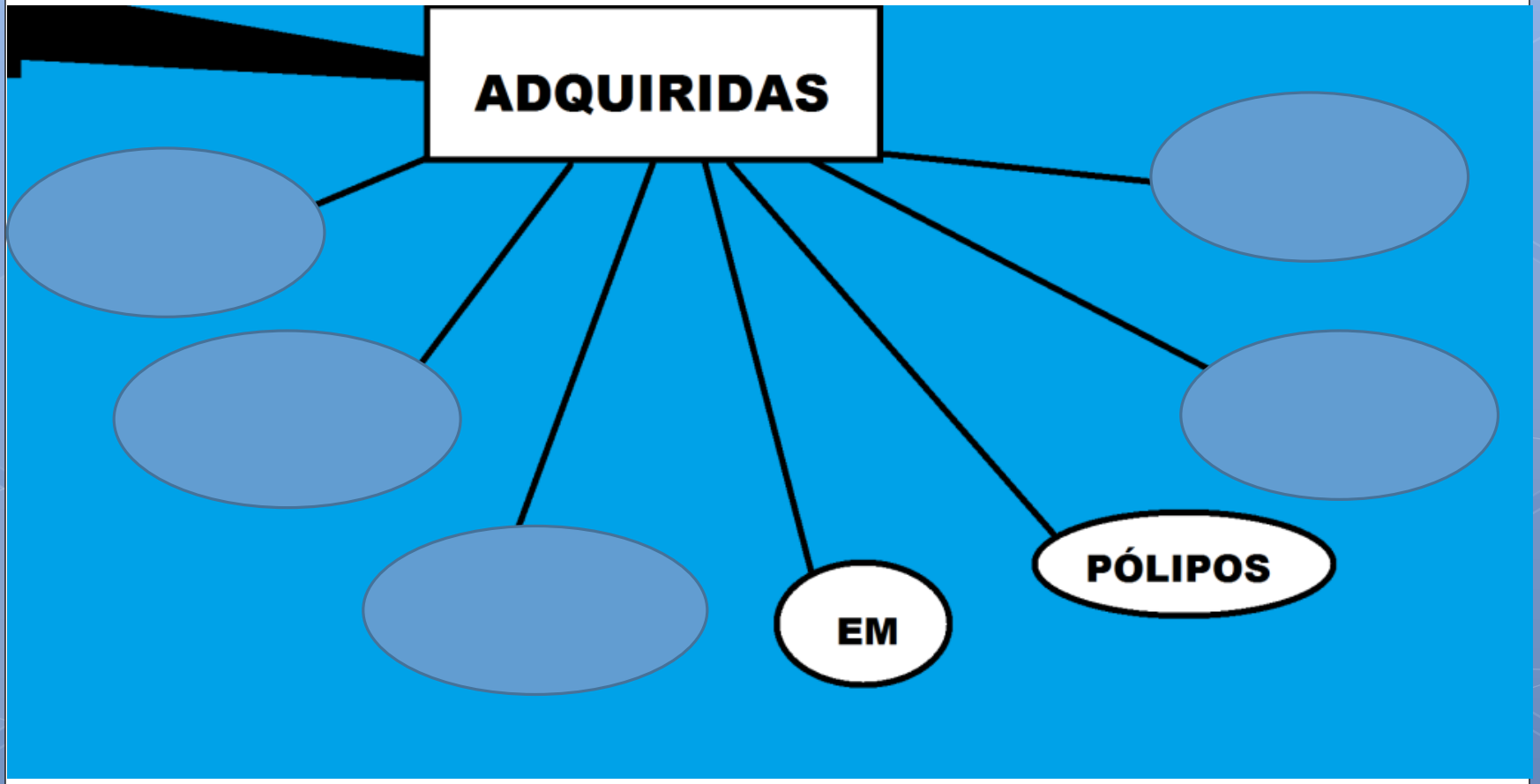
ADQUIRIDAS
PÓLIPOS
EM

FIGURA 7

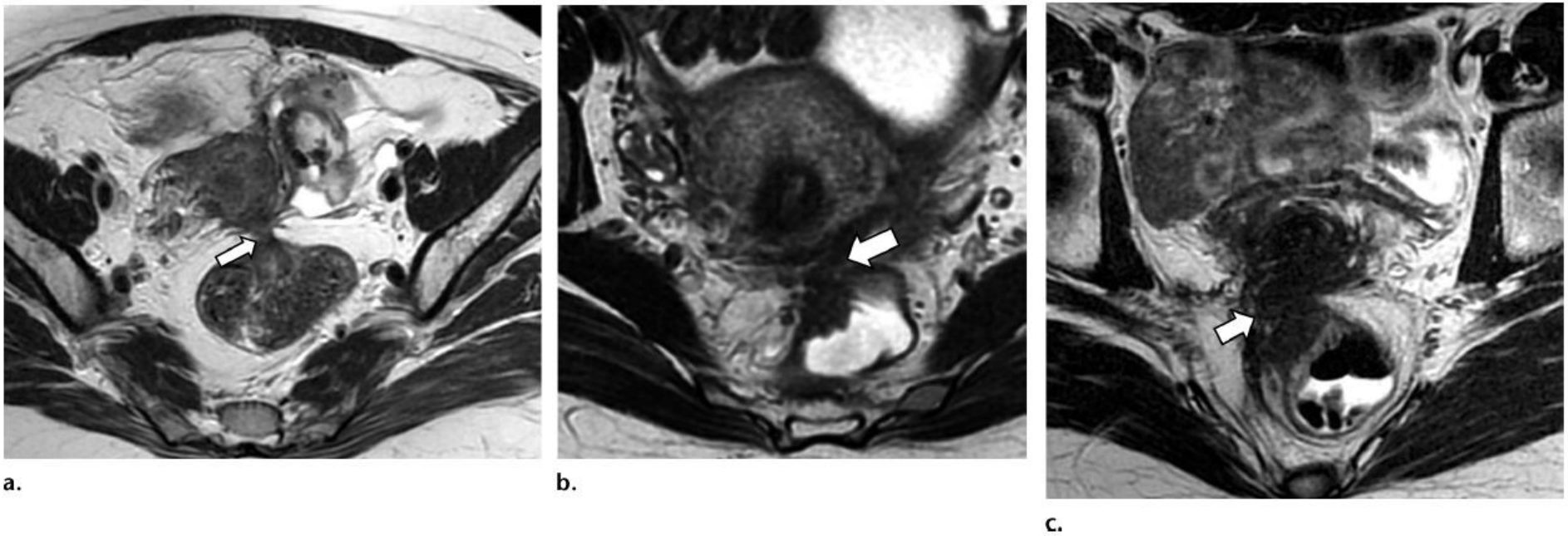

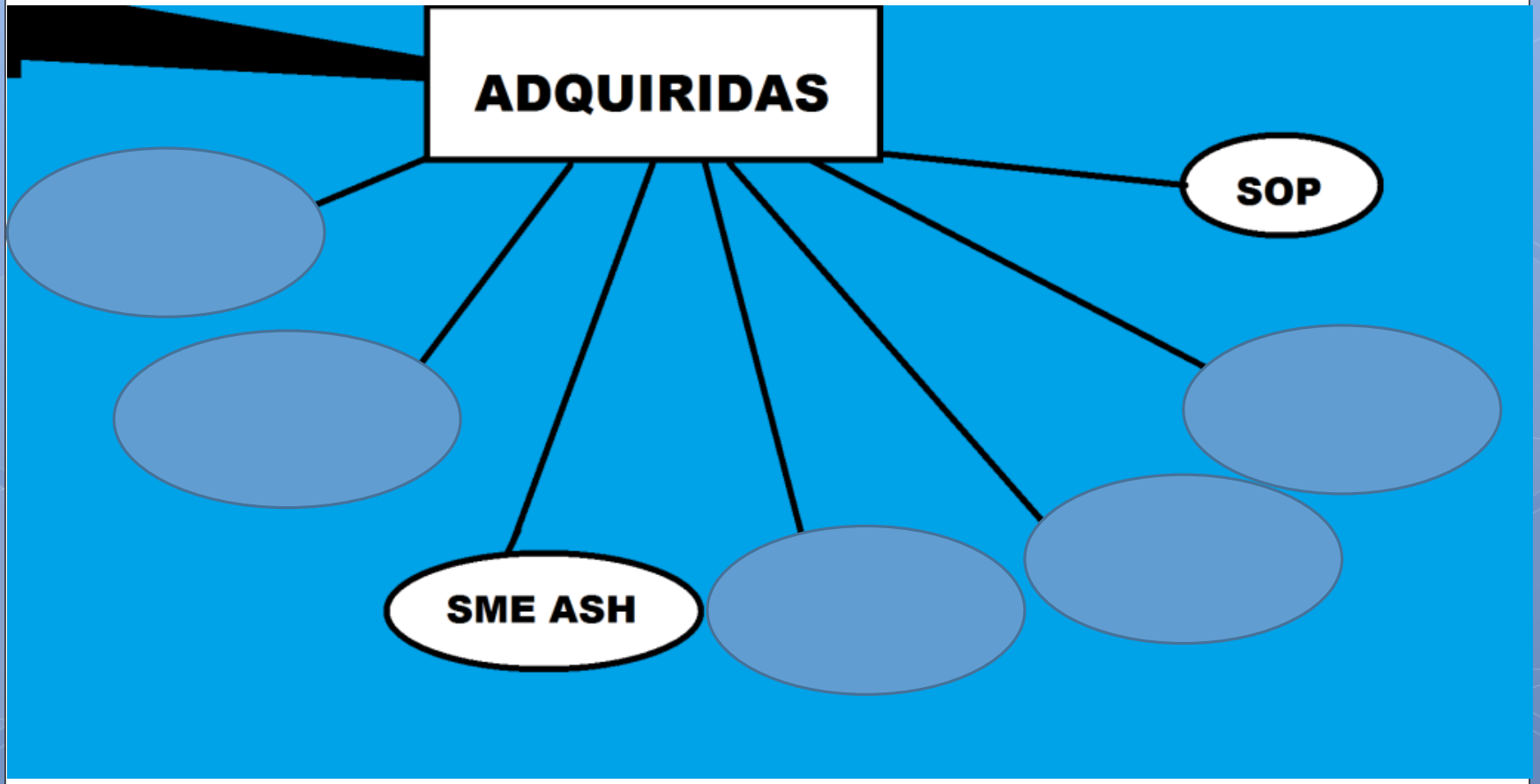
ADQUIRIDAS
SOP
SME ASH

FIGURA 9

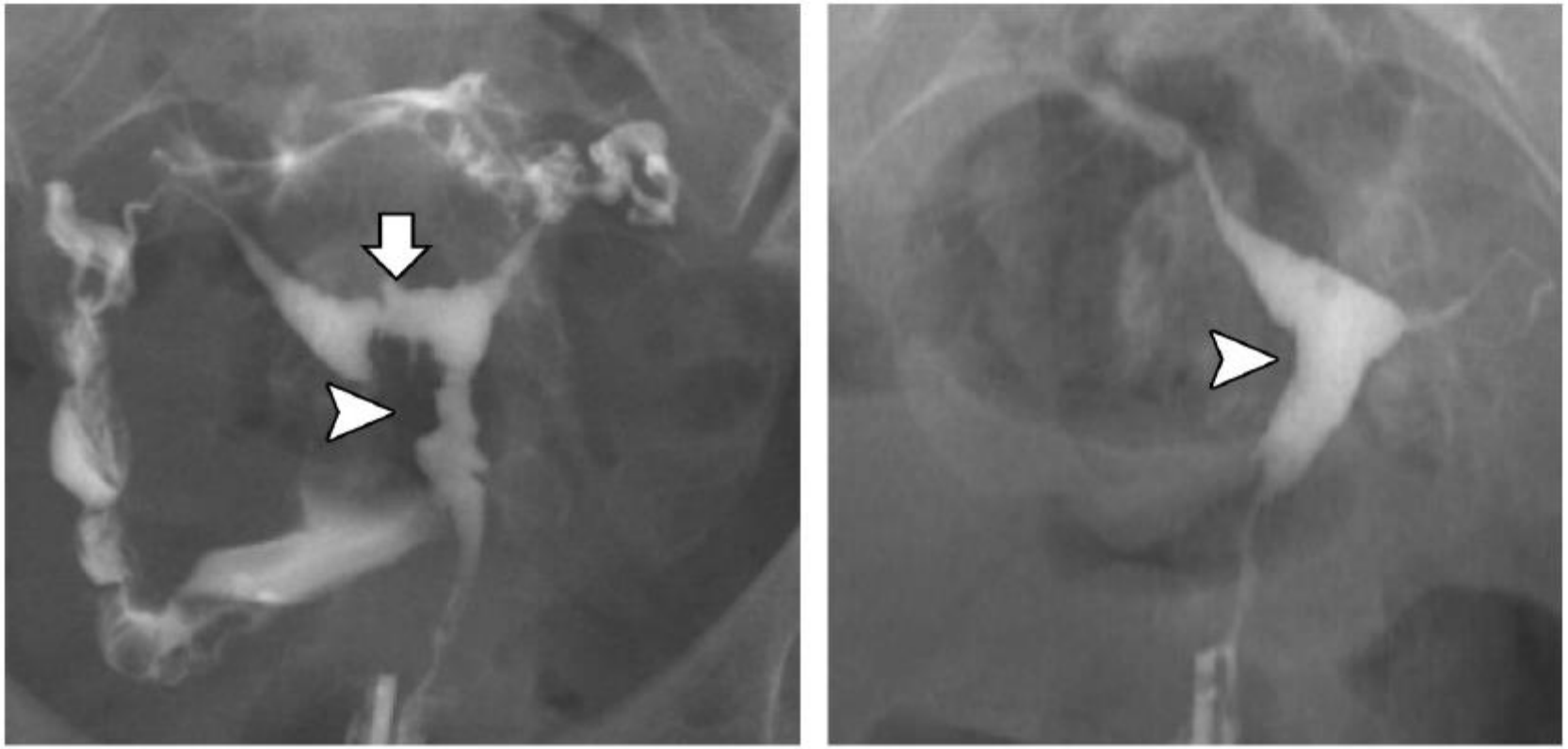

a. b.

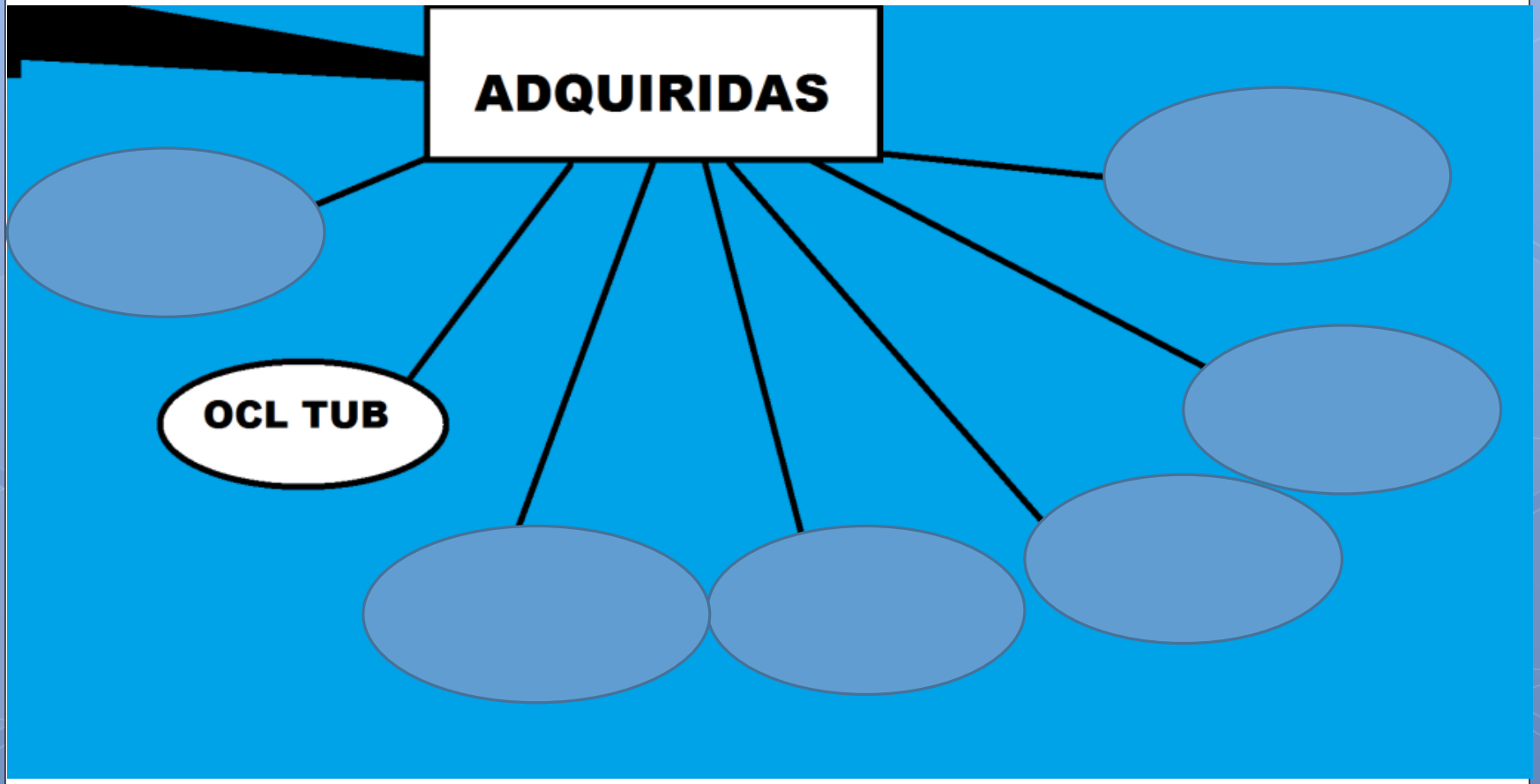
ADQUIRIDAS
OCL TUB

FIGURA 8

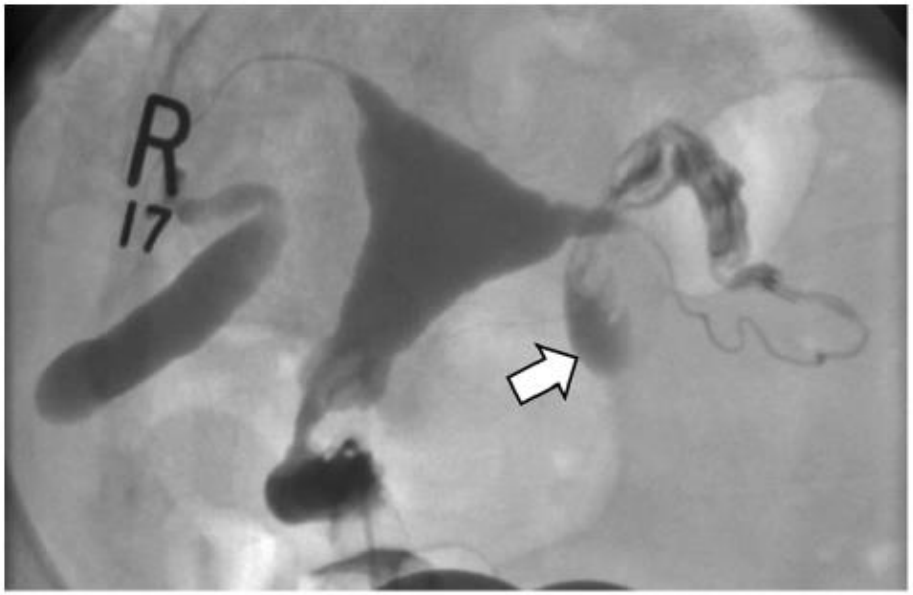

a.

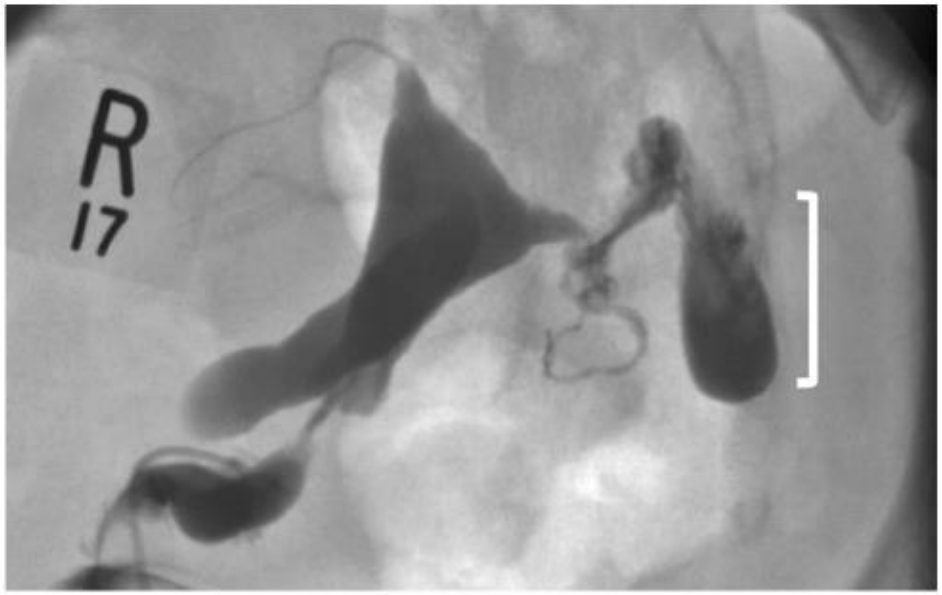

b.

FIGURA 10

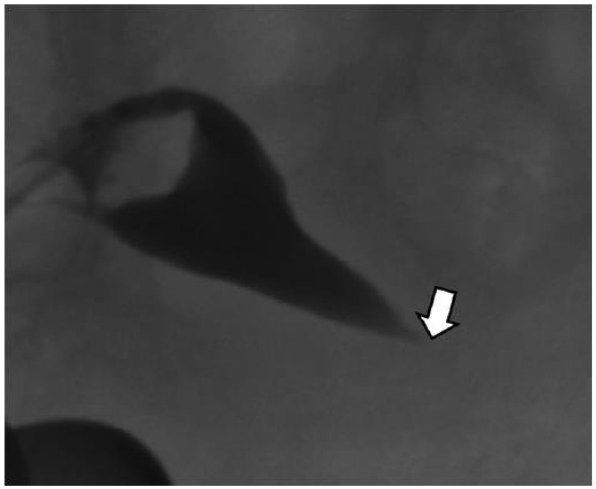

a.

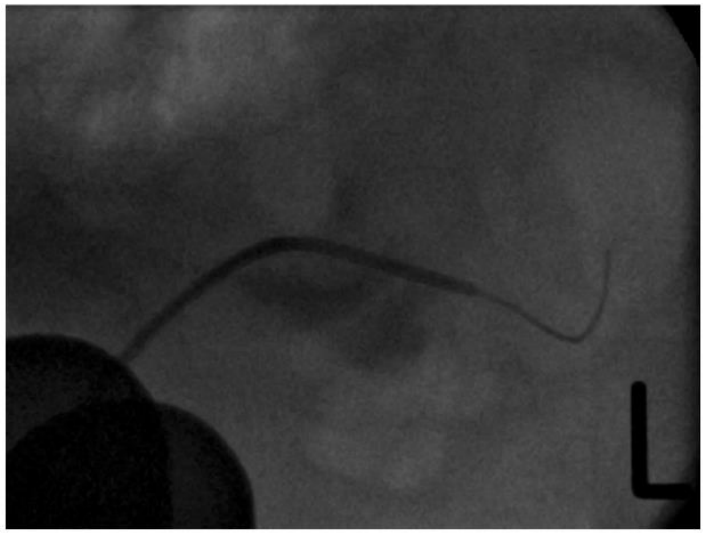

b.

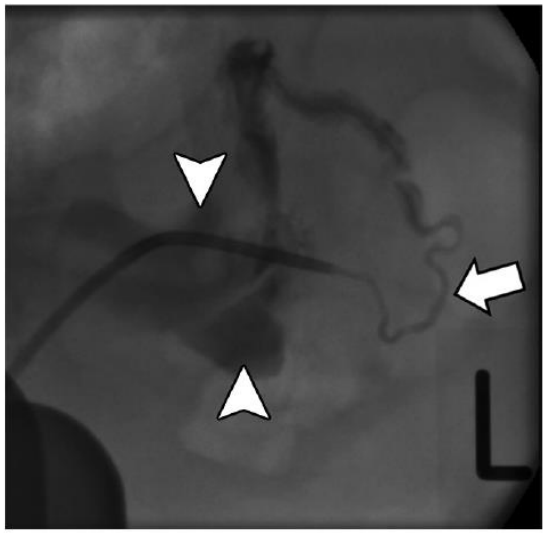

c.

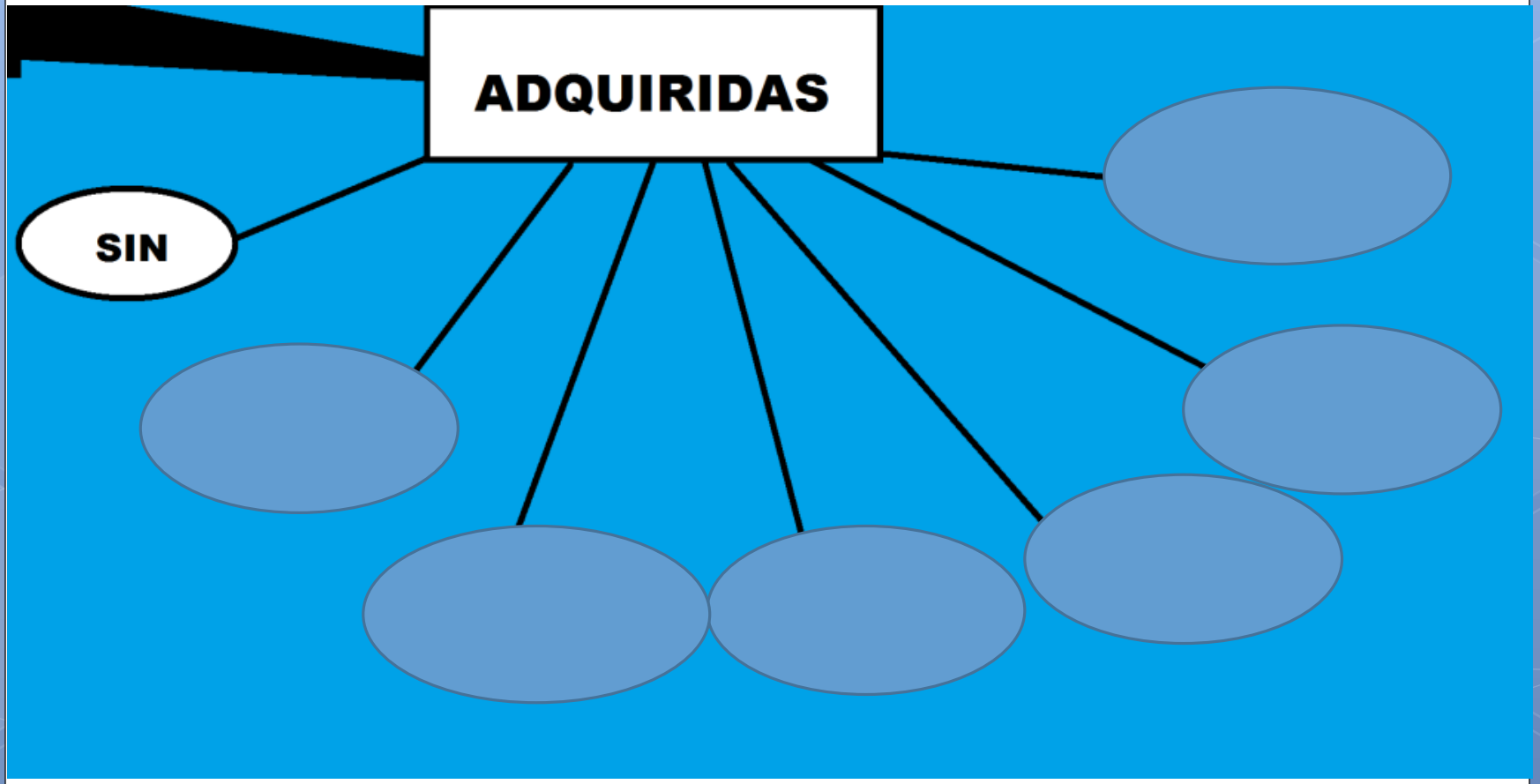
ADQUIRIDAS
SIN

FIGURA 11

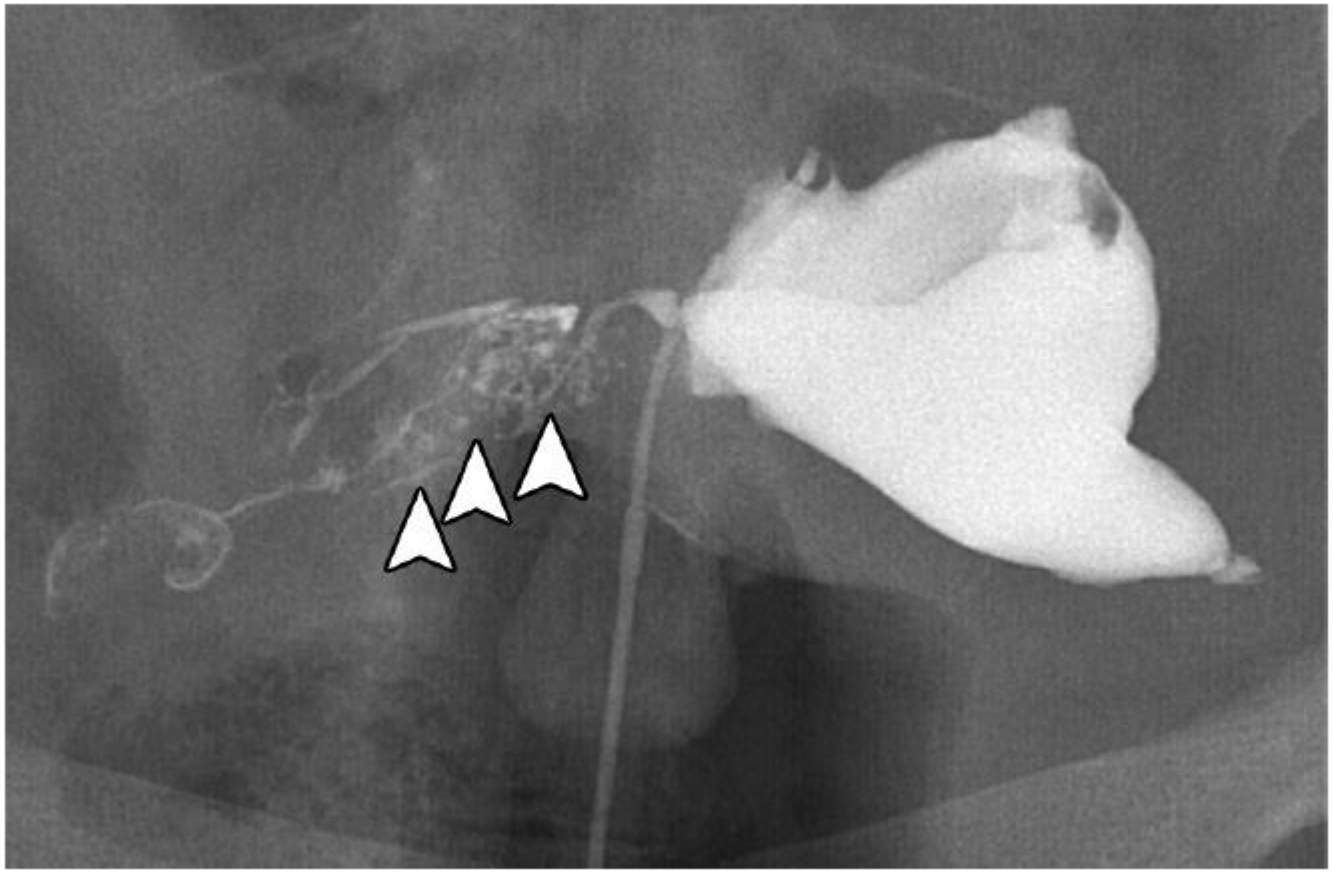

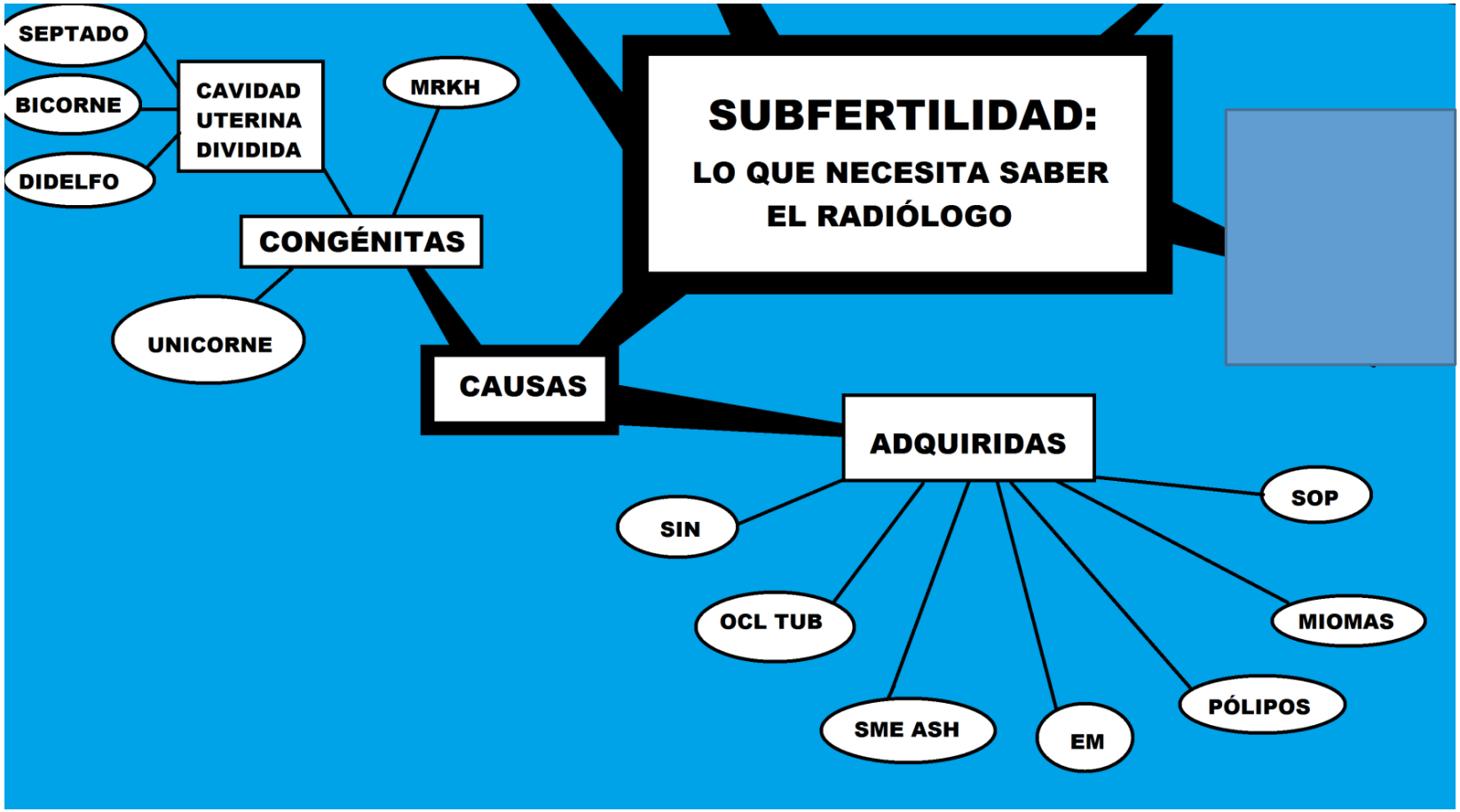
SUBFERTILIDAD:
LO QUE NECESITA SABER EL RADIÓLOGO
CAUSAS
CONGÉNITAS
CAVIDAD UTERINA DIVIDIDA
SEPTADO
BICORNE
DIDELFO
MRKH
UNICORNE
ADQUIRIDAS
SIN
OCL TUB
SME ASH
EM
PÓLIPOS
MIOMAS
SOP

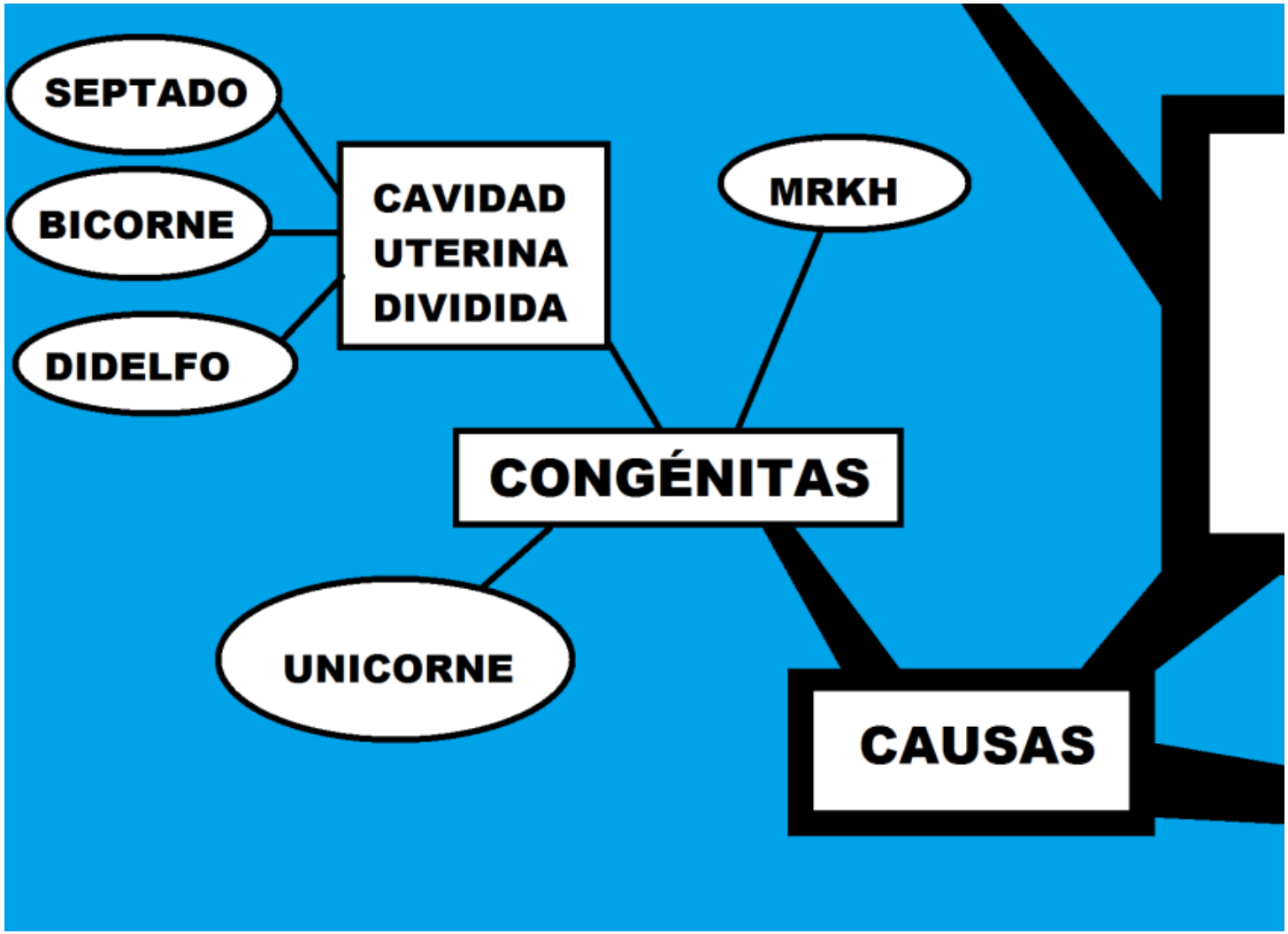
SEPTADO
BICORNE
DIDELFO
CAVIDAD UTERINA DIVIDIDA
MRKH
CONGÉNITAS
UNICORNE
CAUSAS



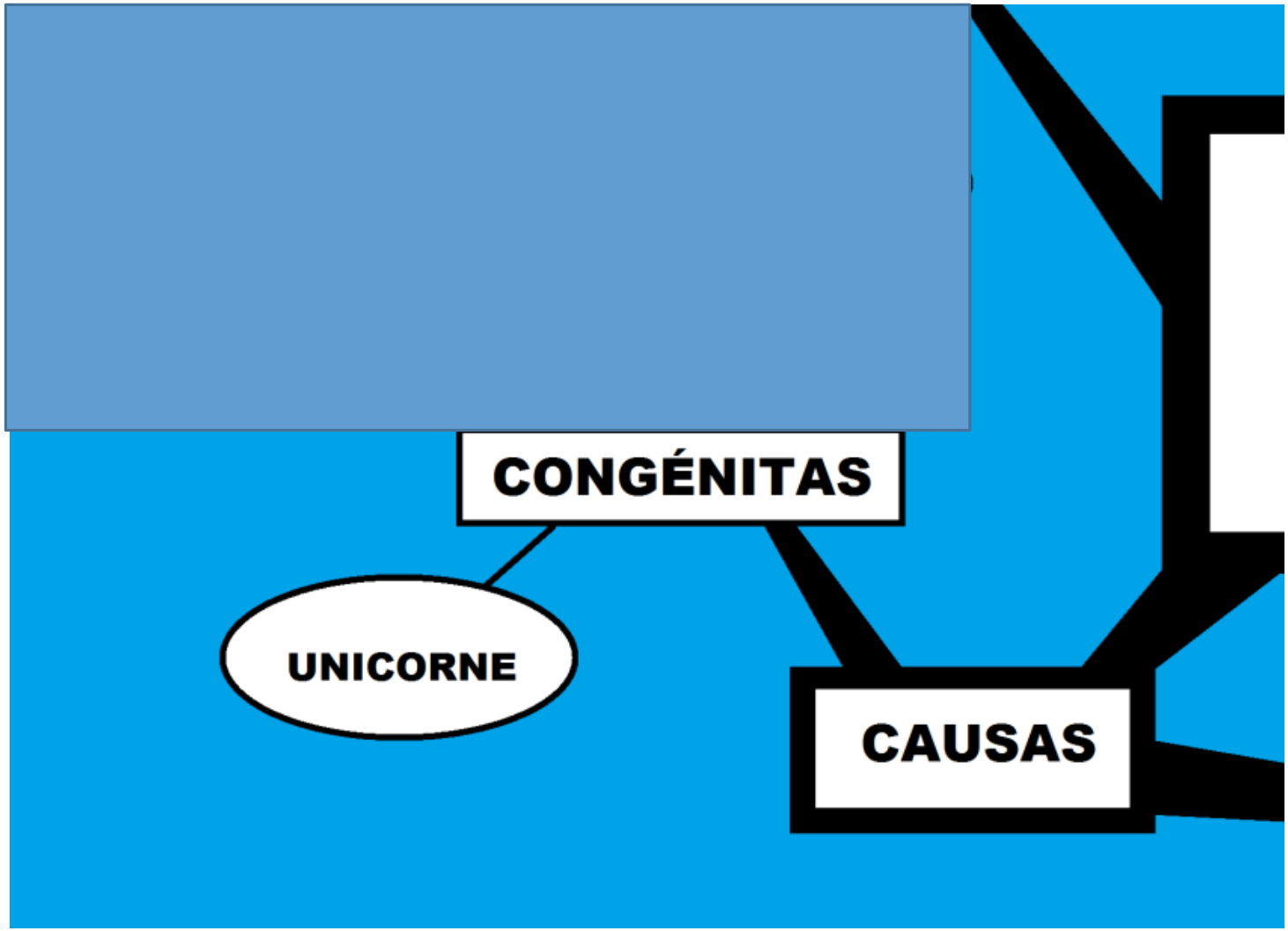
CONGÉNITAS
UNICORNE
CAUSAS

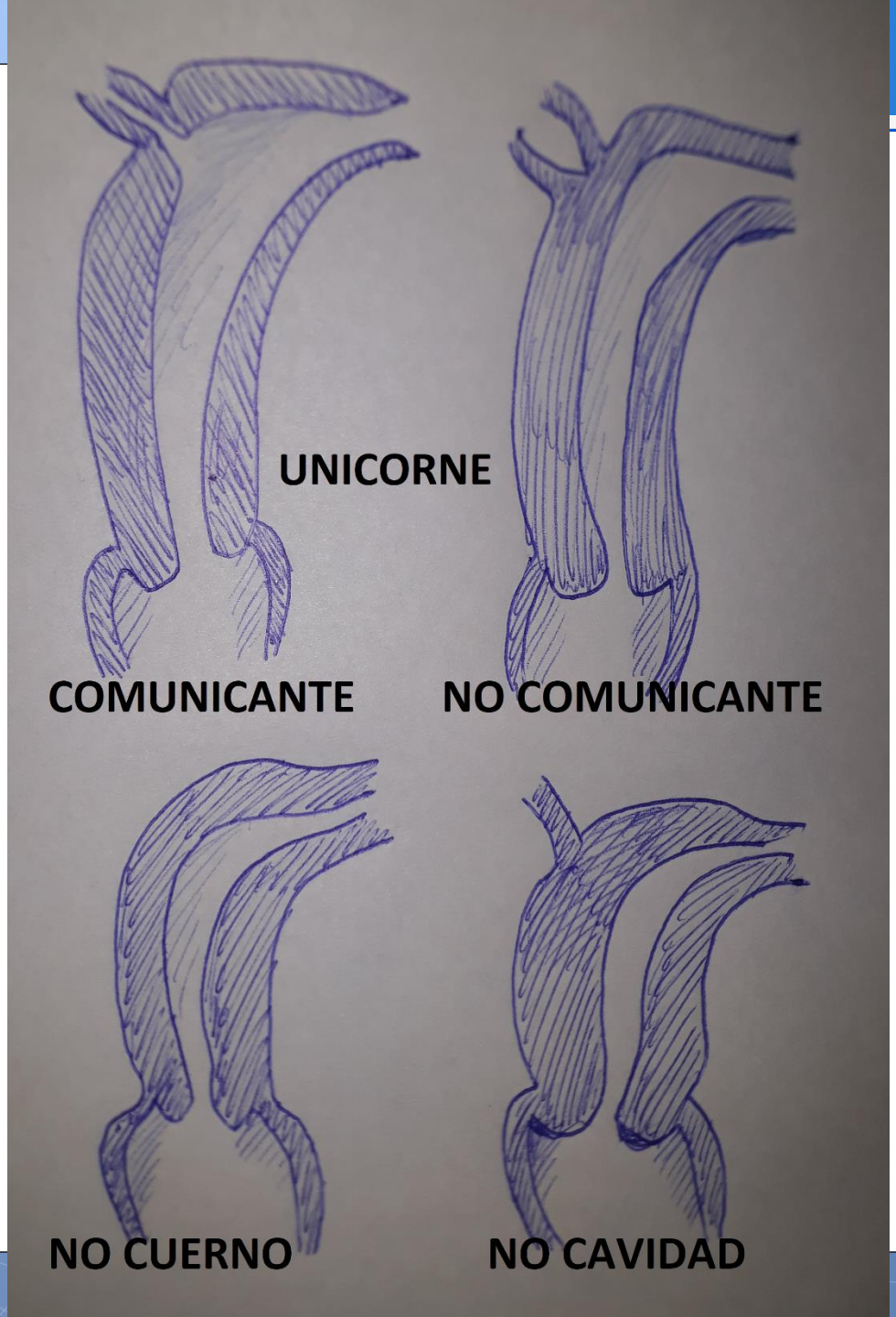
UNICORNE
COMUNICANTE
NO COMUNICANTE
NO CUERNO
NO CAVIDAD

FIGURA 12

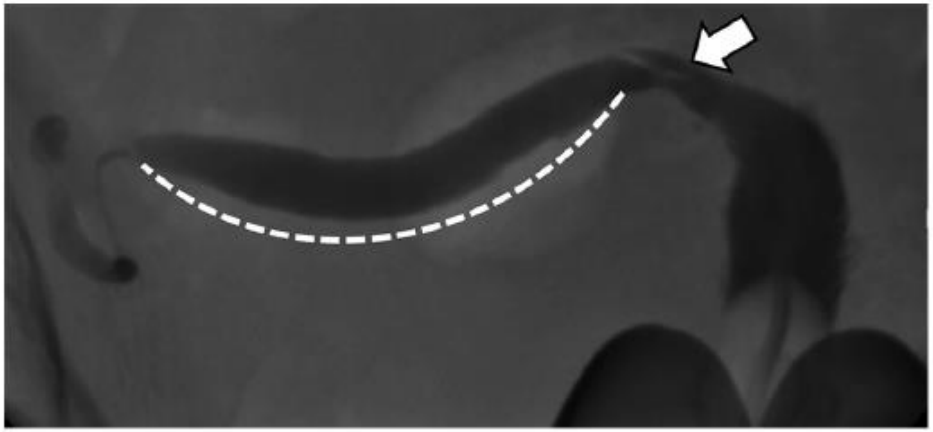

a.

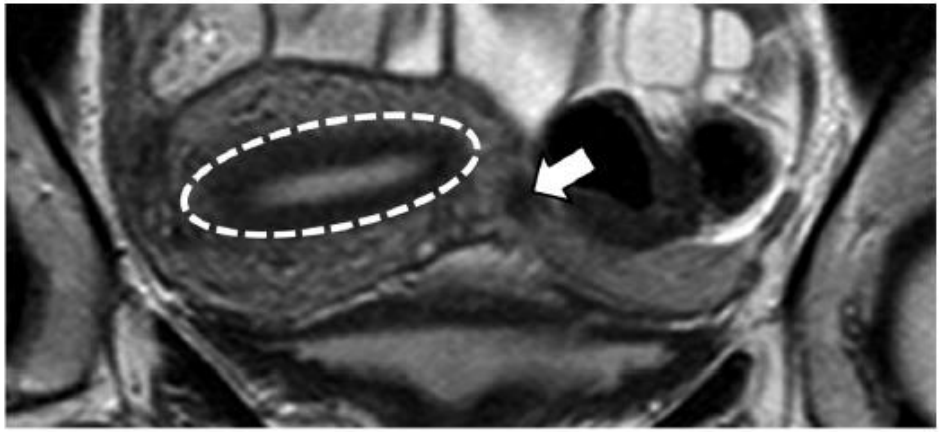

b.

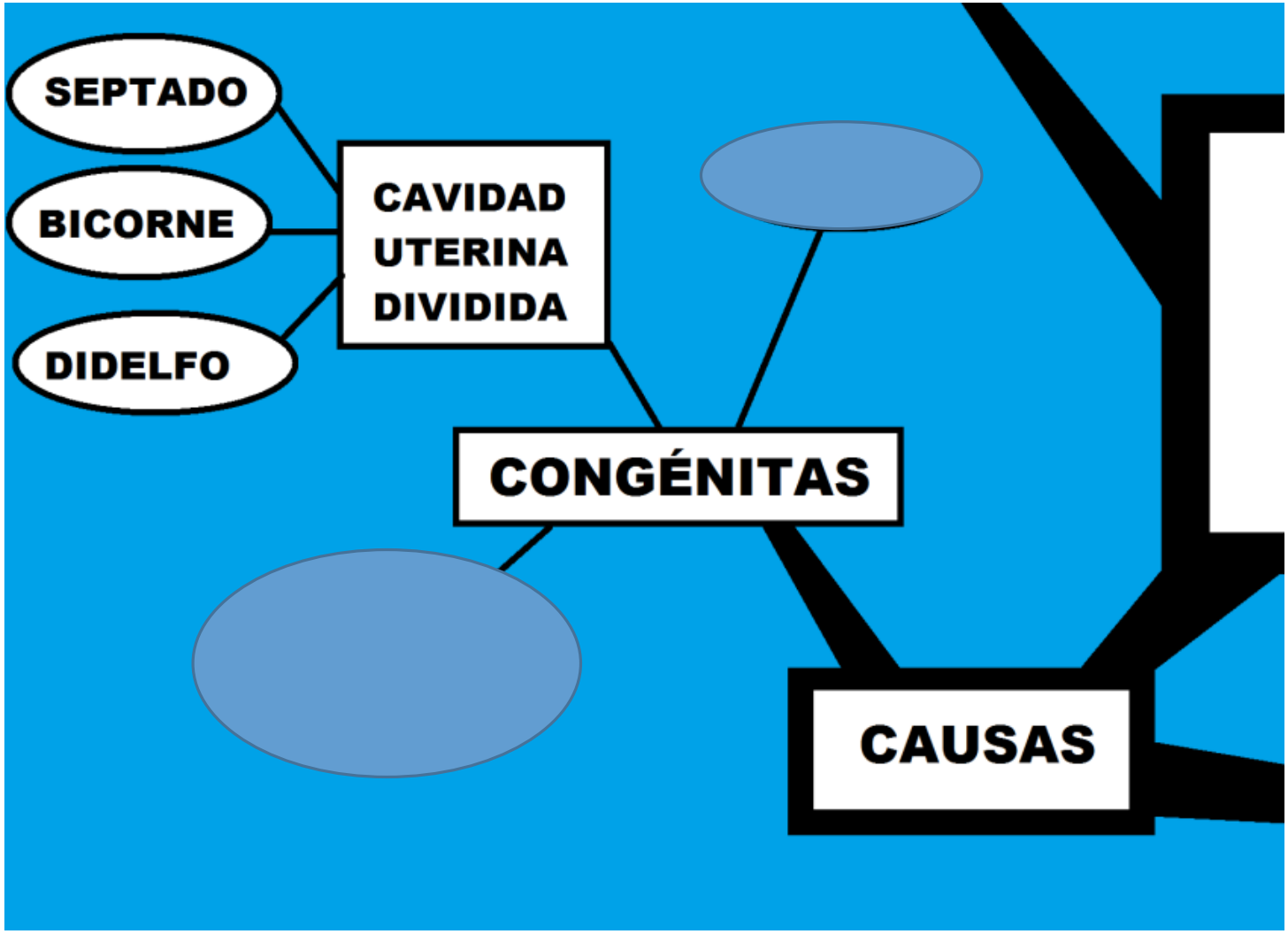
SEPTADO
BICORNE
DIDELFO
CAVIDAD UTERINA DIVIDIDA
CONGÉNITAS
CAUSAS



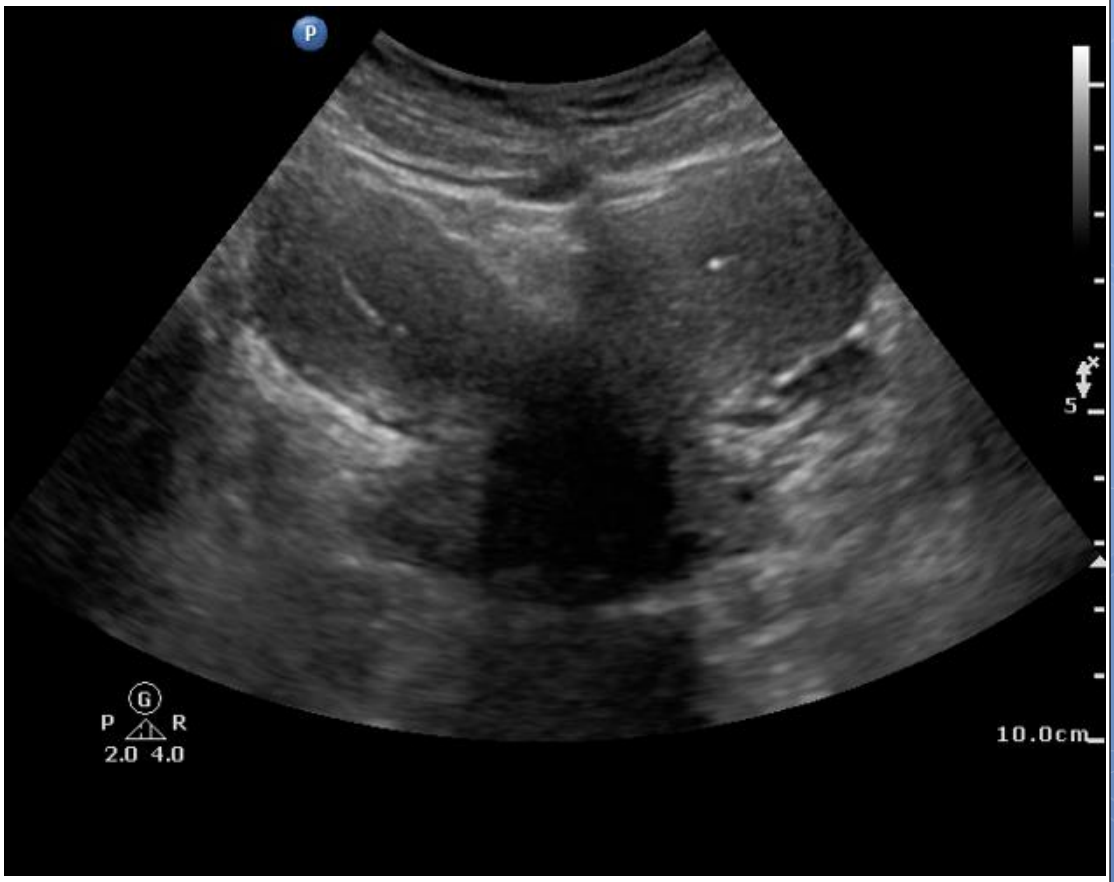
P
G
P
R
2.0 4.0
5
10.0cm

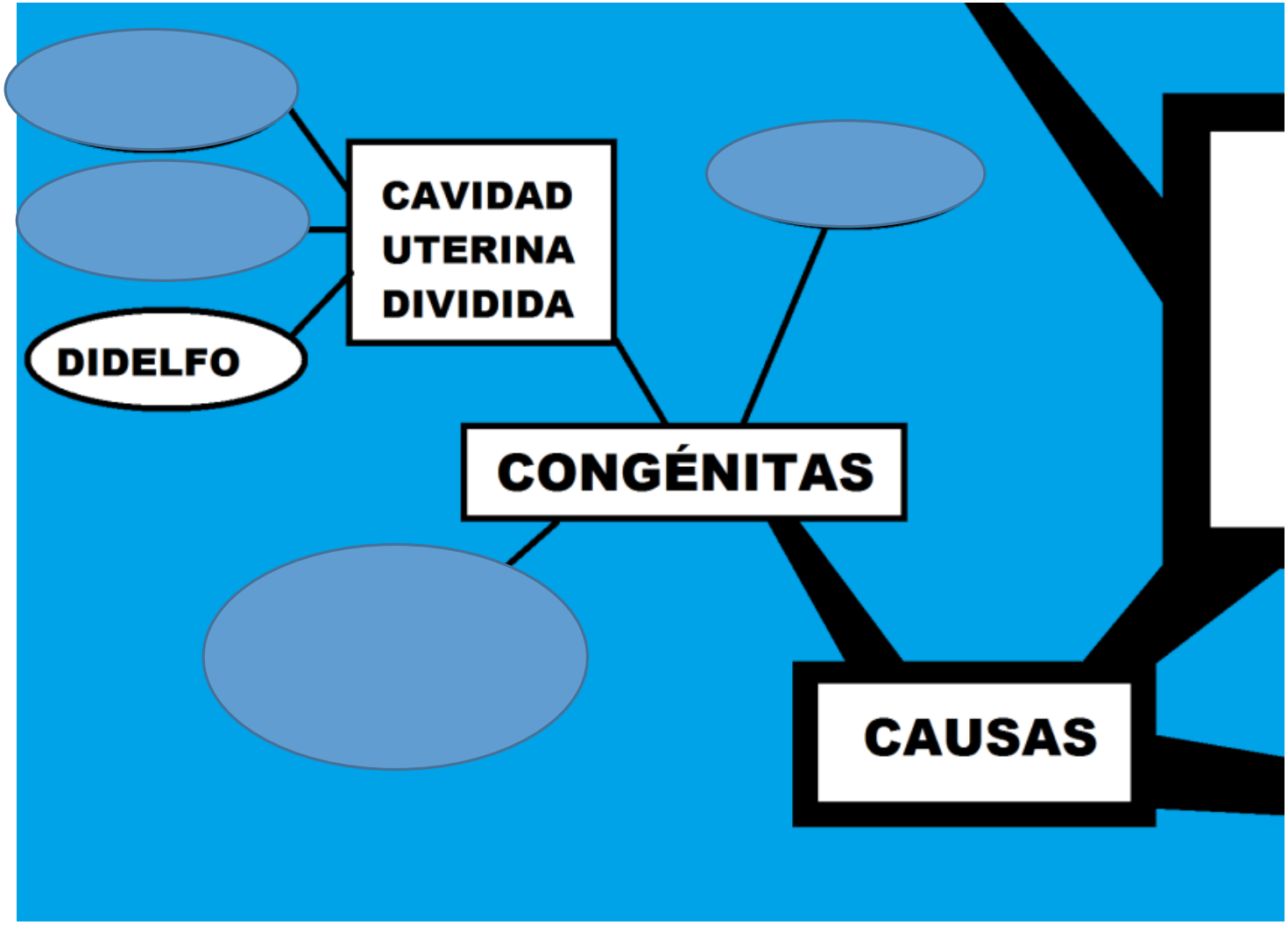
CAVIDAD
UTERINA
DIVIDIDA
DIDELFO
CONGÉNITAS
CAUSAS


DIDELFO

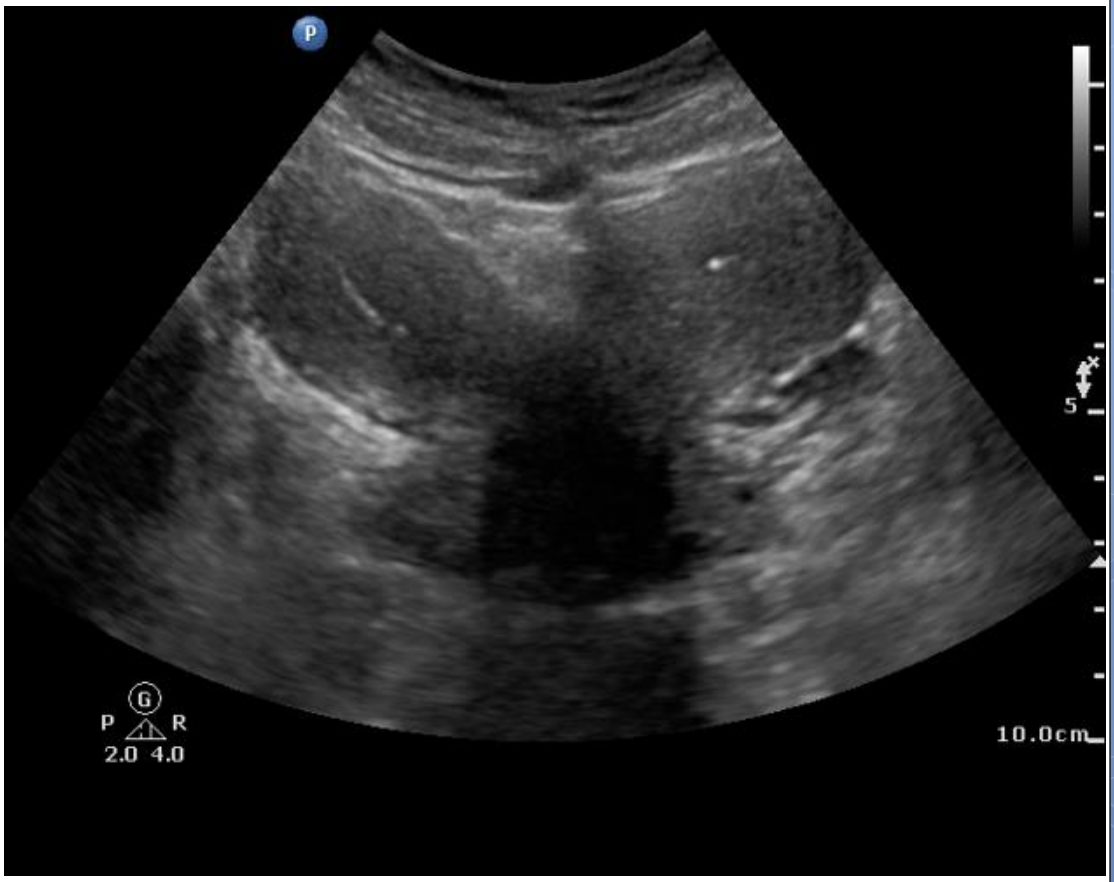
P
G
P R
2.0 4.0
10.0cm
5

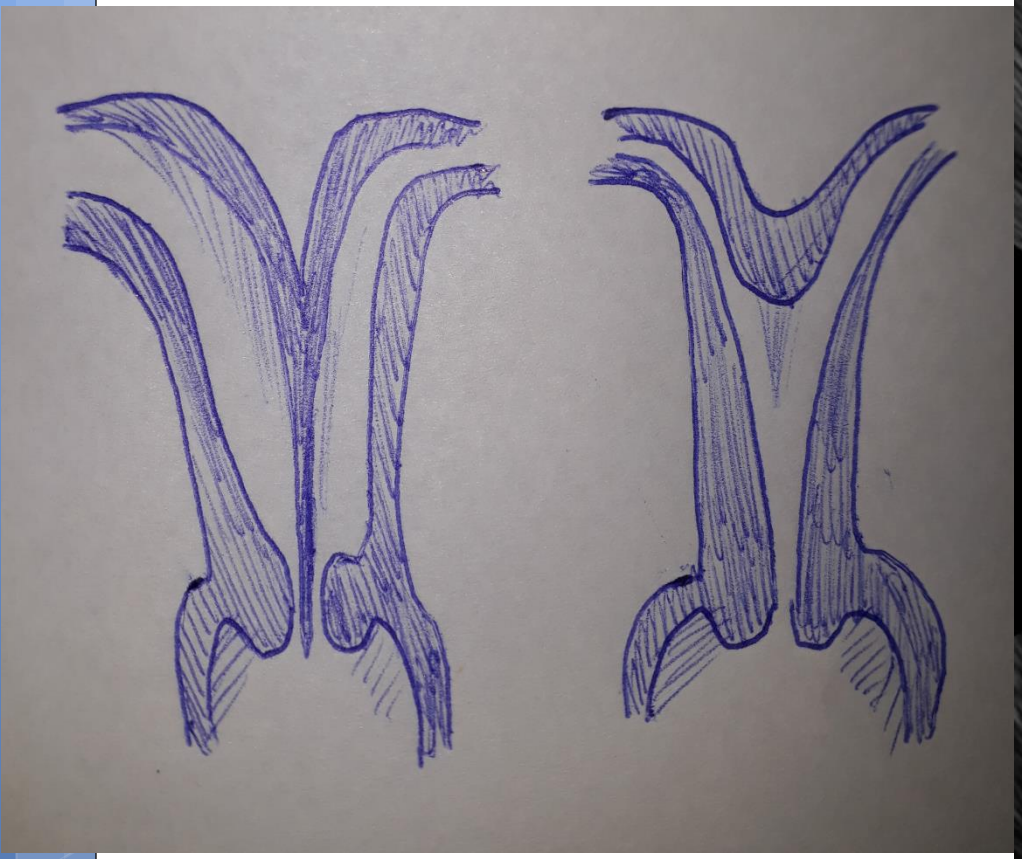

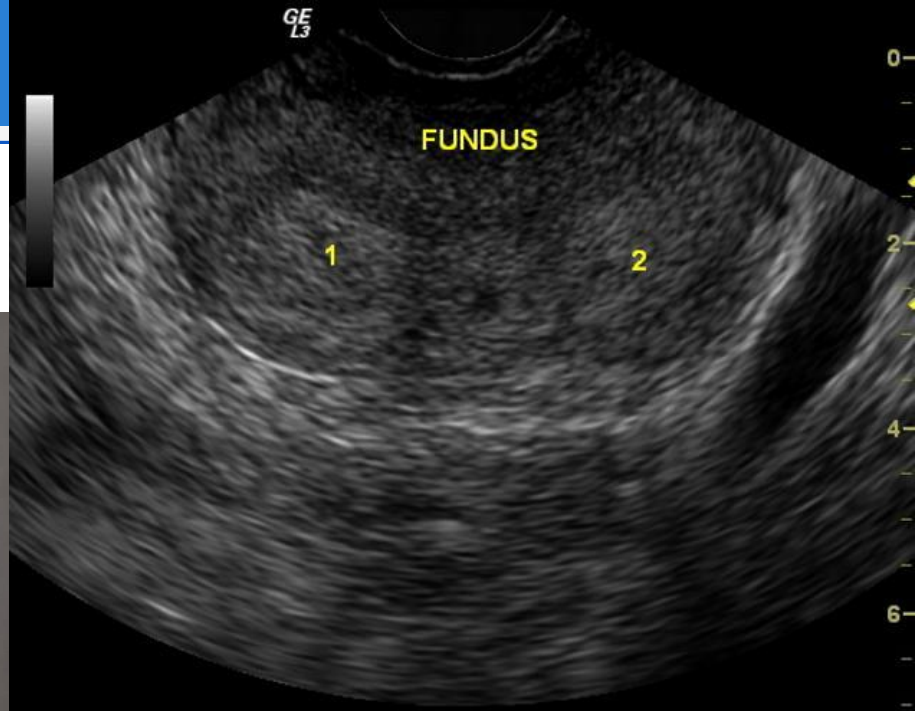
GE
L3
FUNDUS
1
2
0
2
4
6

GE
L3
BODY
0
2
4
6

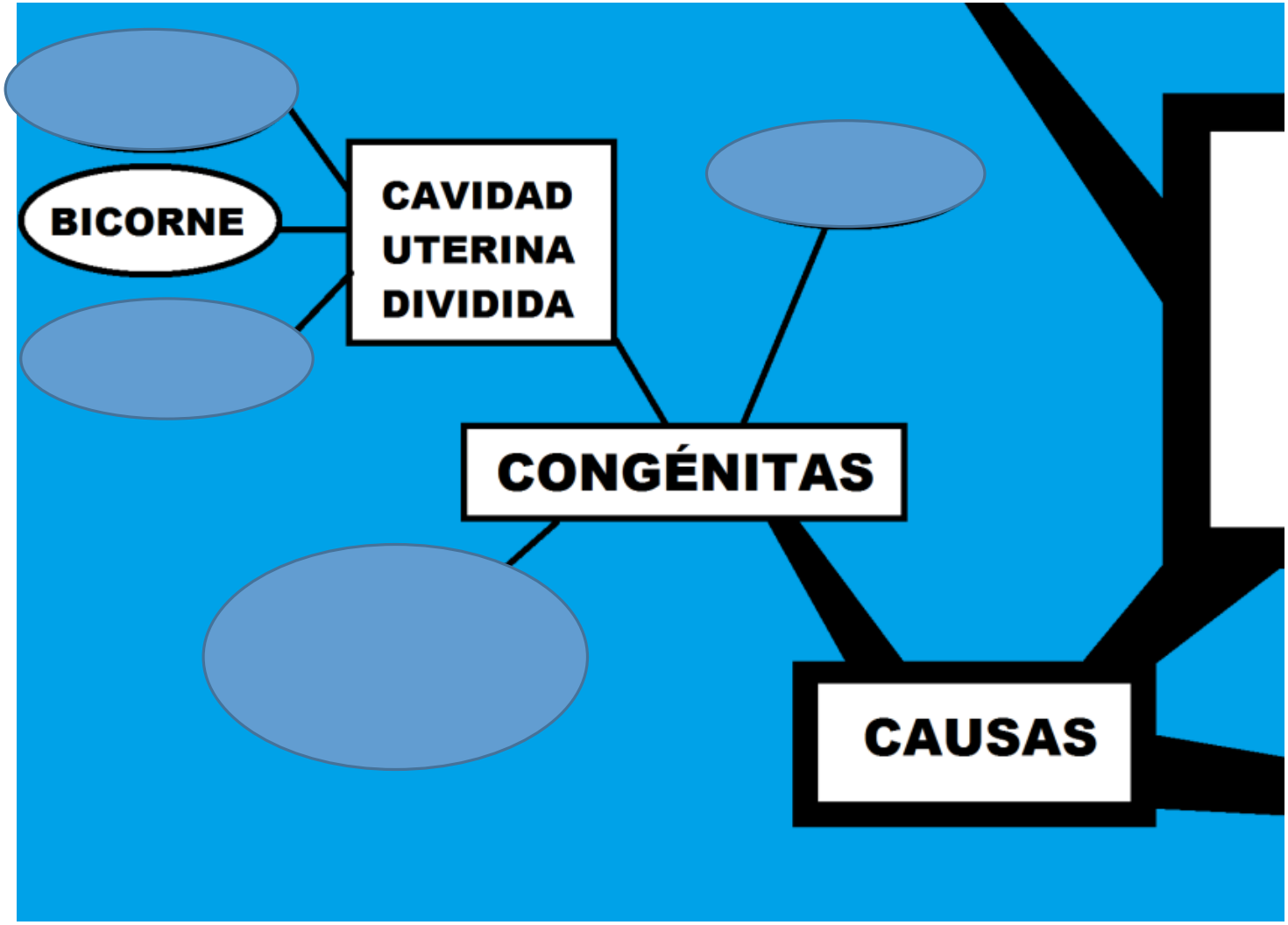
BICORNE
CAVIDAD UTERINA DIVIDIDA
CONGÉNITAS
CAUSAS

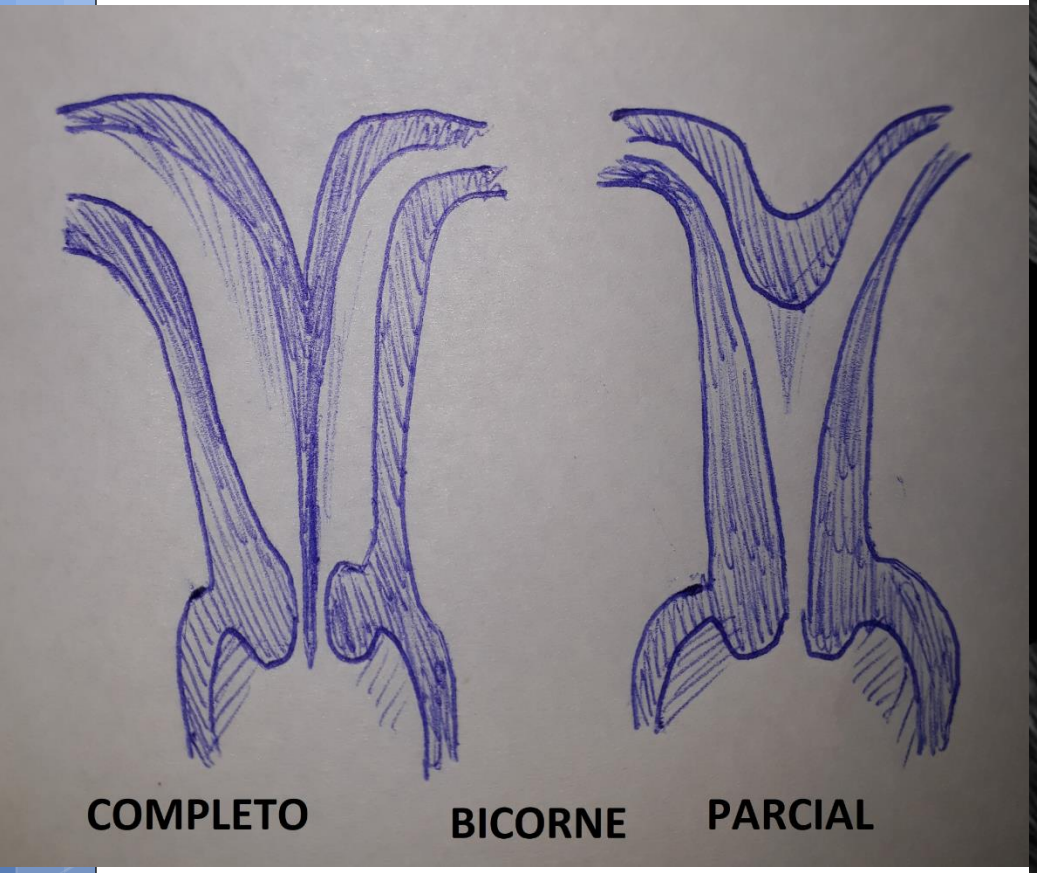
COMPLETO
BICORNE
PARCIAL

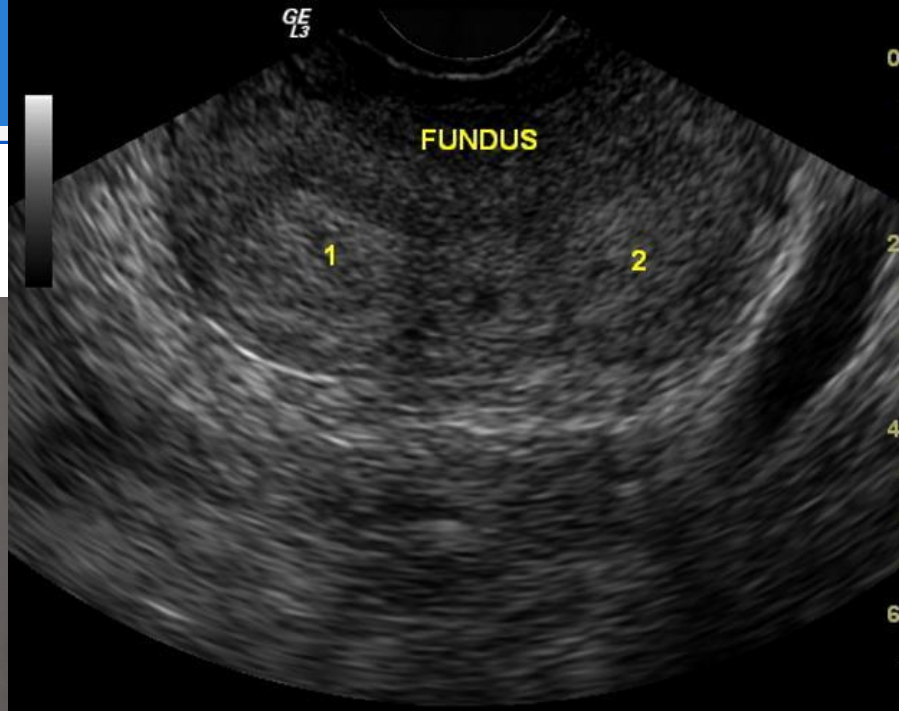
GE
L3
FUNDUS
1
2

GE
L3
BODY

FIGURA 13

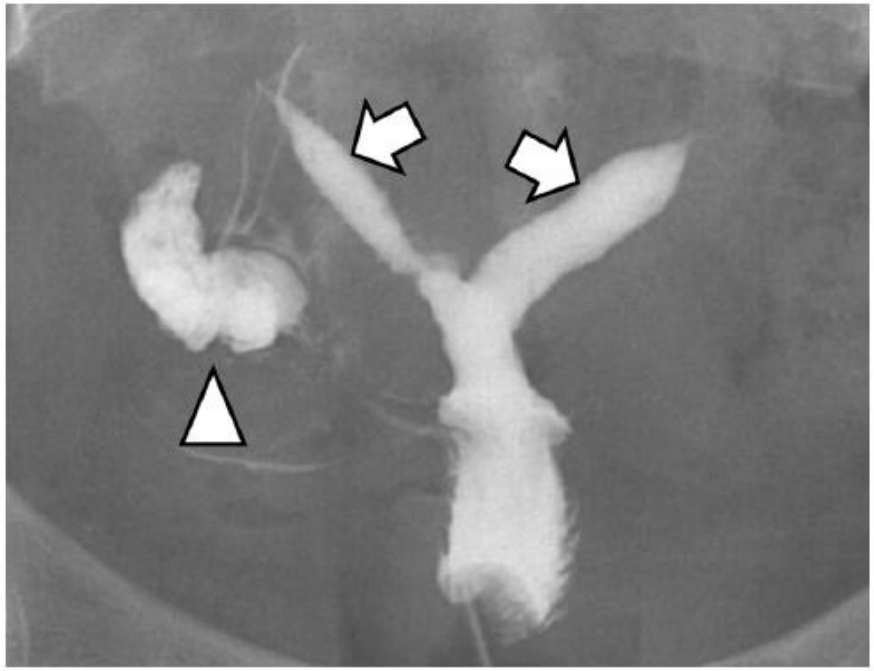

a.

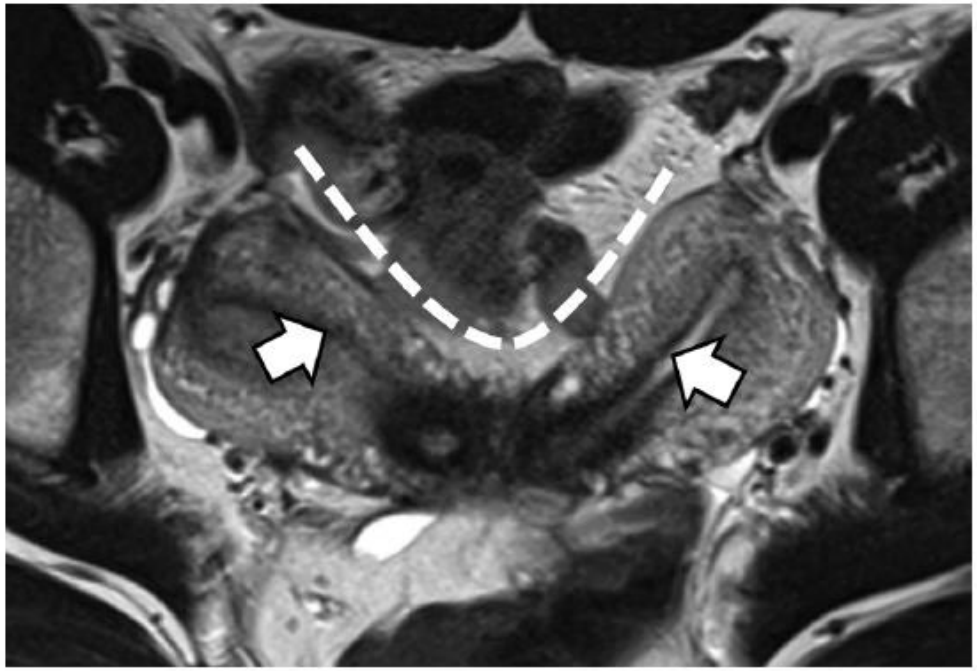

b.

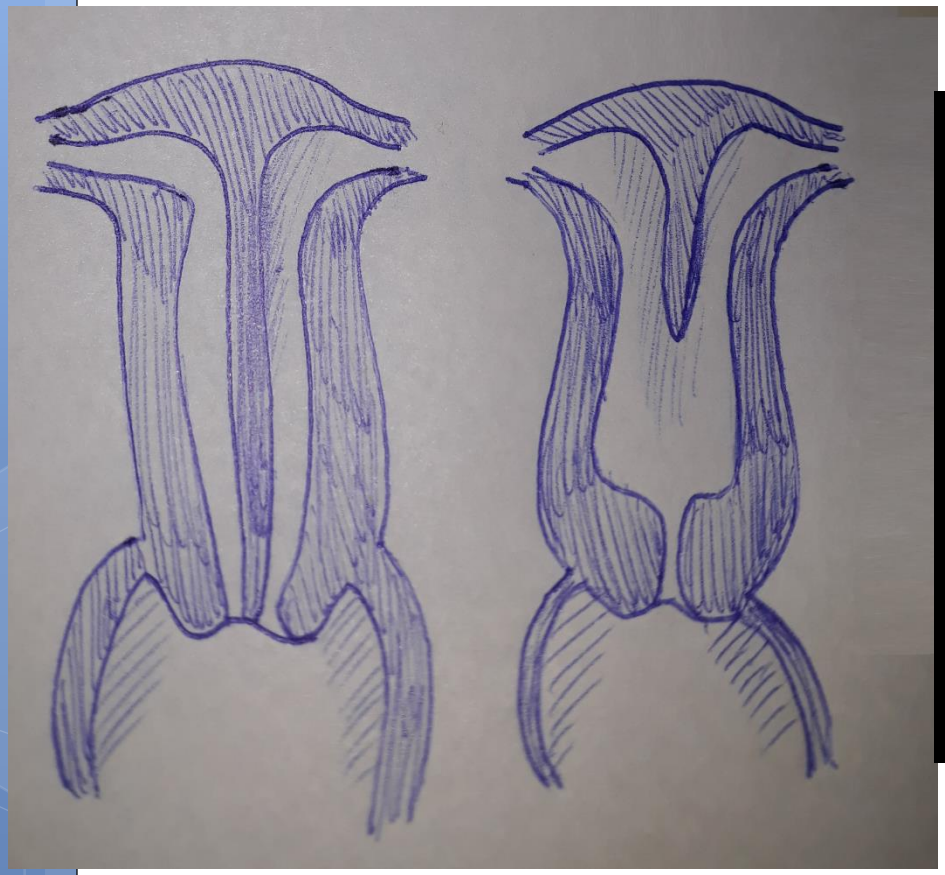

80%
305/306
21Hz
2.11MR R15.0 G60 D63

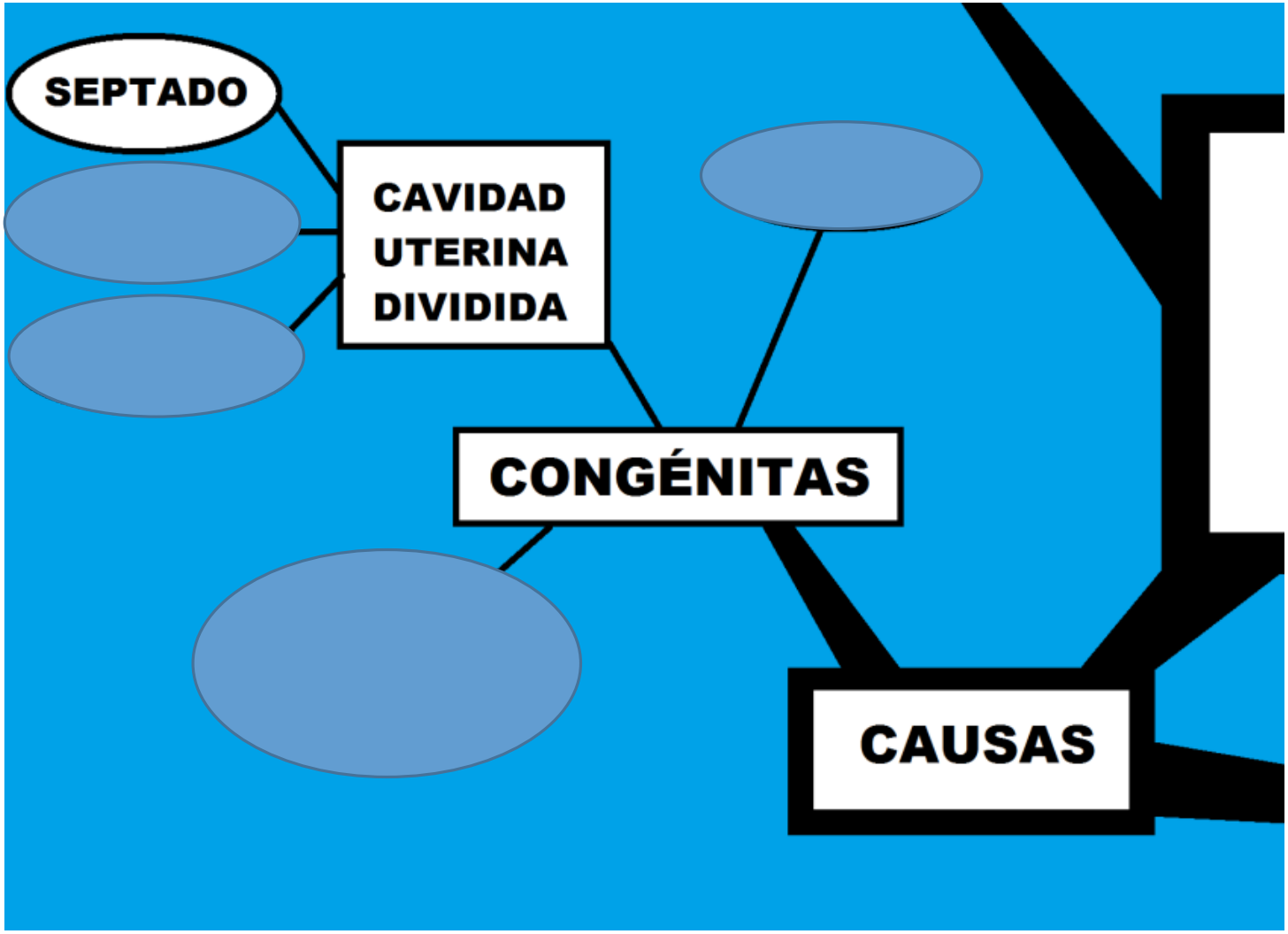
SEPTADO
CAVIDAD UTERINA DIVIDIDA
CONGÉNITAS
CAUSAS

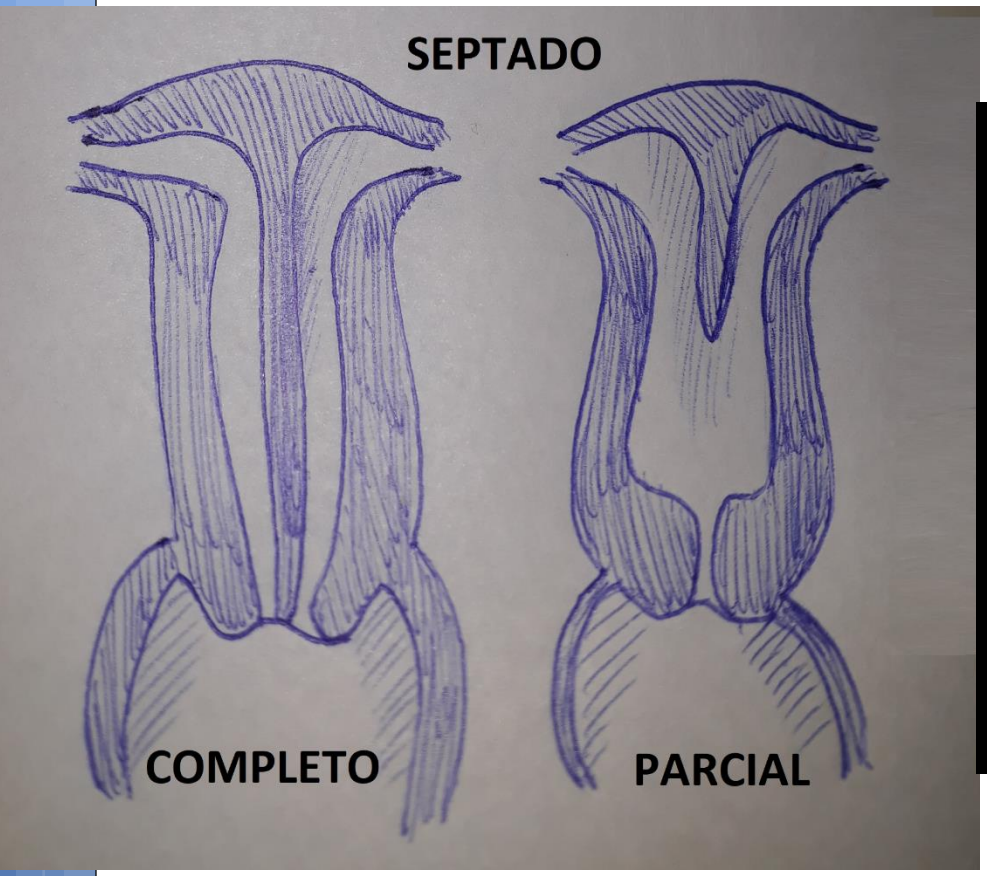
SEPTADO
COMPLETO
PARCIAL

80%
305/306
21Hz
2.11MR R15.0 G60 D63

FIGURA 14

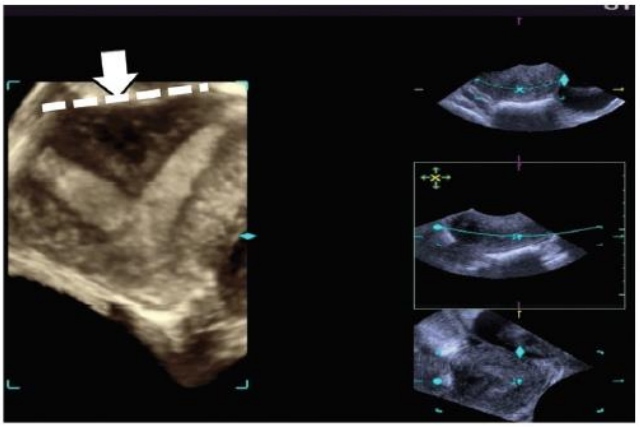

a.

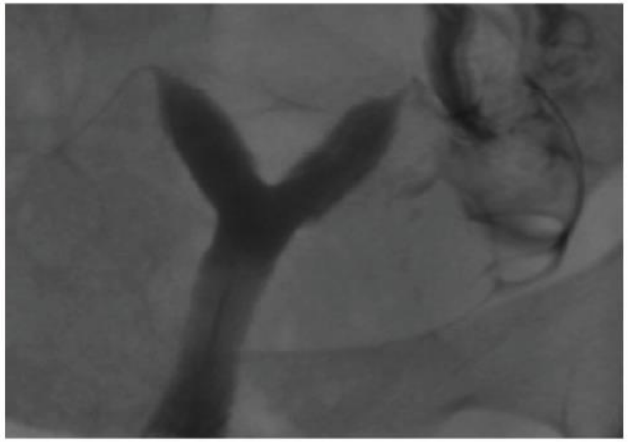

b.

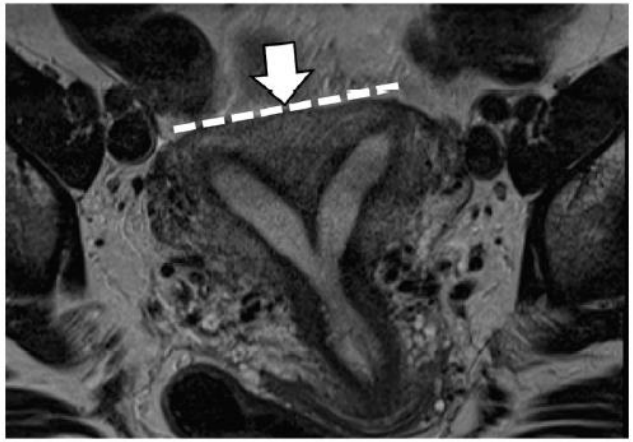

c.

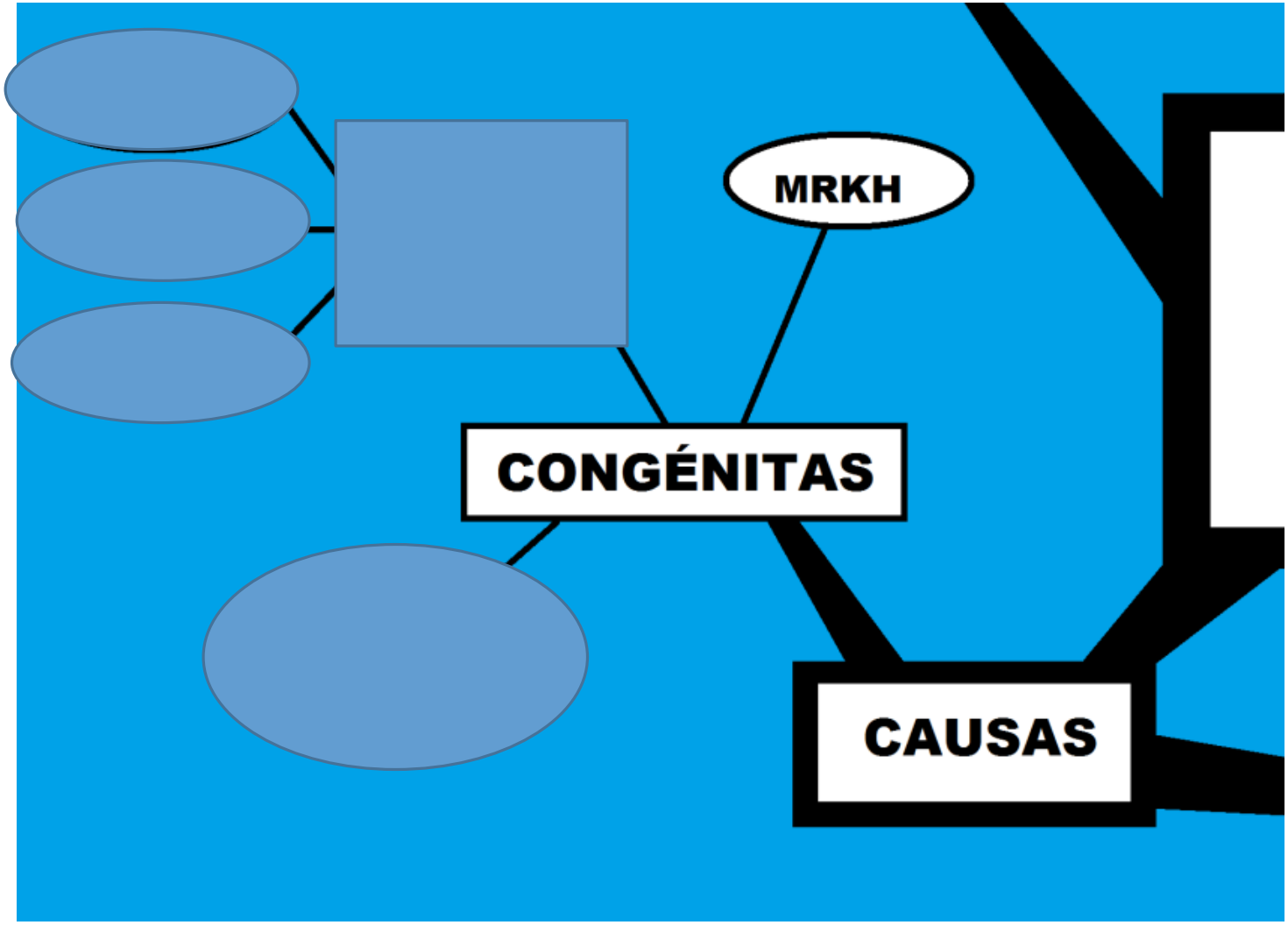
MRKH
CONGÉNITAS
CAUSAS

FIGURA 15

a.

b.

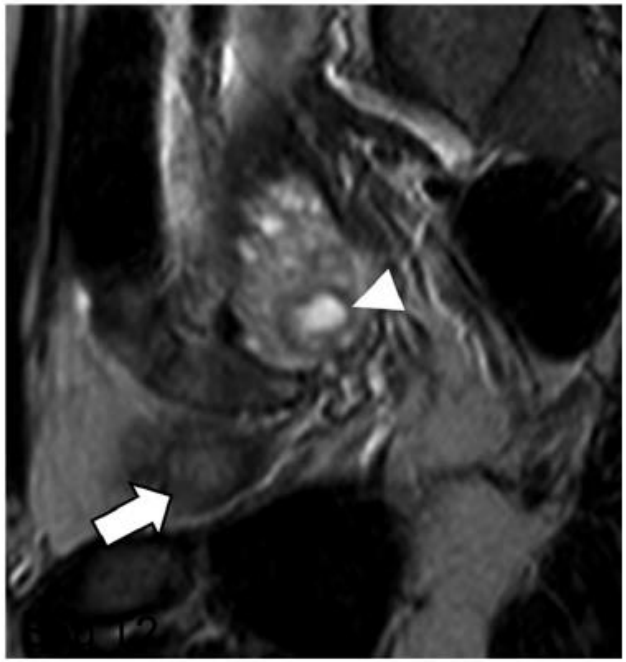

c.

Table 3: Causes of Absolute UFI

Congenital absence of uterus (MRKH syndrome)
Hysterectomy due to obstetric complications (eg, postpartum hemorrhage)
Hysterectomy for benign disease (eg, PID, fibroids, pelvic tuberculosis)
Early invasive cervical or ovarian malignancy at early age (<30 y)

Source.—Reference 66.
Note.—PID = pelvic inflammatory disease.

THE LANCET
FULL TEXT ARTICLE

Case Reports Lancet. 2015 Feb 14;385(9968):607-616. doi: 10.1016/S0140-6736(14)61728-1. Epub 2014 Oct 6.

Livebirth After Uterus Transplantation

Mats Brännström [1], Liza Johannesson [2], Hans Bokström [3], Niclas Kvarnström [4], Johan Mölne [5], Pernilla Dahm-Kähler [2], Anders Enskog [6], Milan Milenkovic [2], Jana Ekberg [4], Cesar Diaz-Garcia [7], Markus Gäbel [4], Ash Hanafy [8], Henrik Hagberg [9], Michael Olausson [4], Lars Nilsson [2]

Affiliations
PMID: 25301505 DOI: 10.1016/S0140-6736(14)61728-1

Abstract

Background: Uterus transplantation is the first available treatment for absolute uterine infertility, which is caused by absence of the uterus or the presence of a non-functional uterus. Eleven human uterus transplantation attempts have been done worldwide but no livebirth has yet been reported.

Methods: In 2013, a 35-year-old woman with congenital absence of the uterus (Rokitansky syndrome) underwent transplantation of the uterus in Sahlgrenska University Hospital, Gothenburg, Sweden. The uterus was donated from a living, 61-year-old, two-parous woman. In-vitro fertilisation treatment of the recipient and her partner had been done before transplantation, from which 11 embryos were cryopreserved.

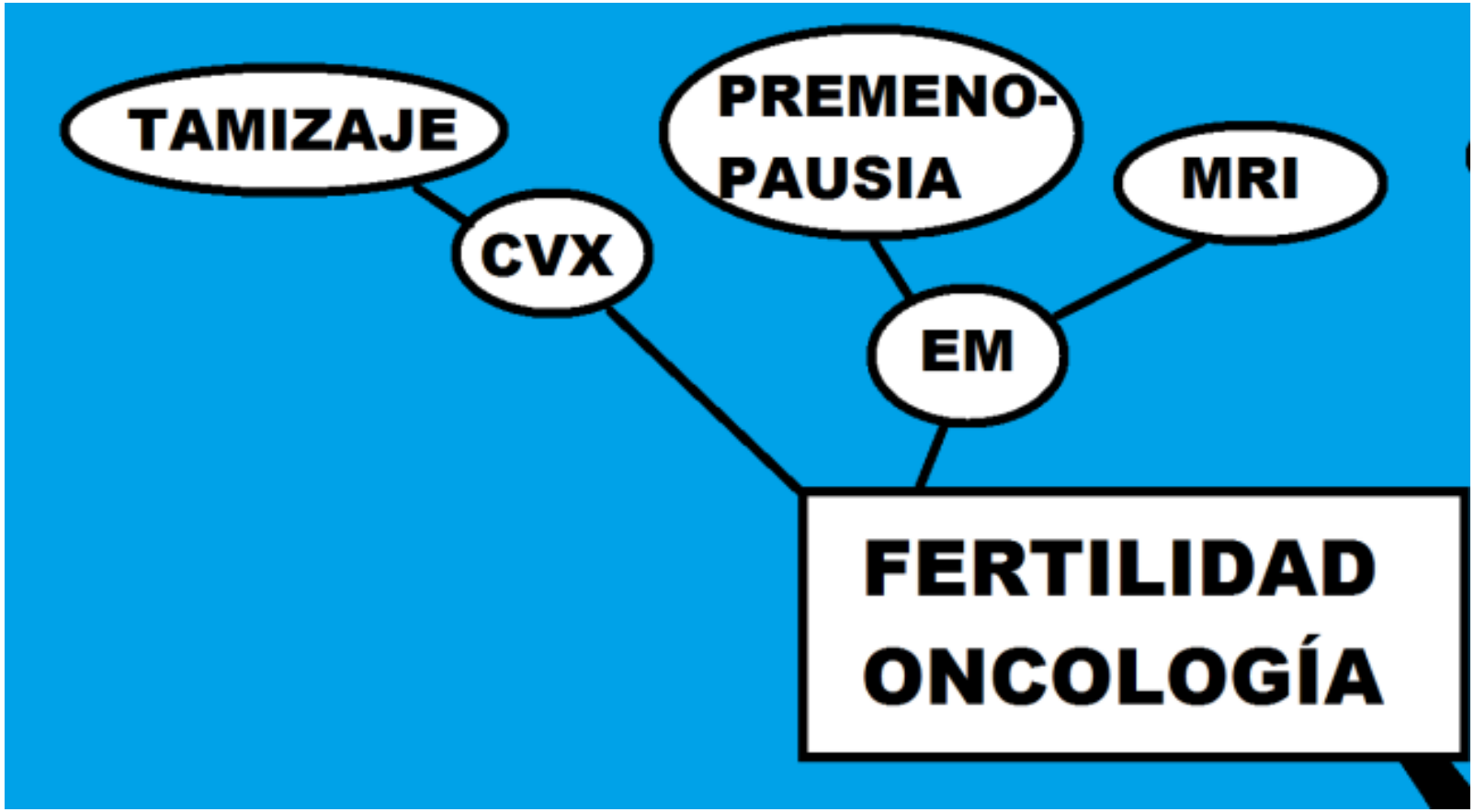
TAMIZAJE
CVX
PREMENO-
PAUSIA
MRI
EM
FERTILIDAD
ONCOLOGÍA

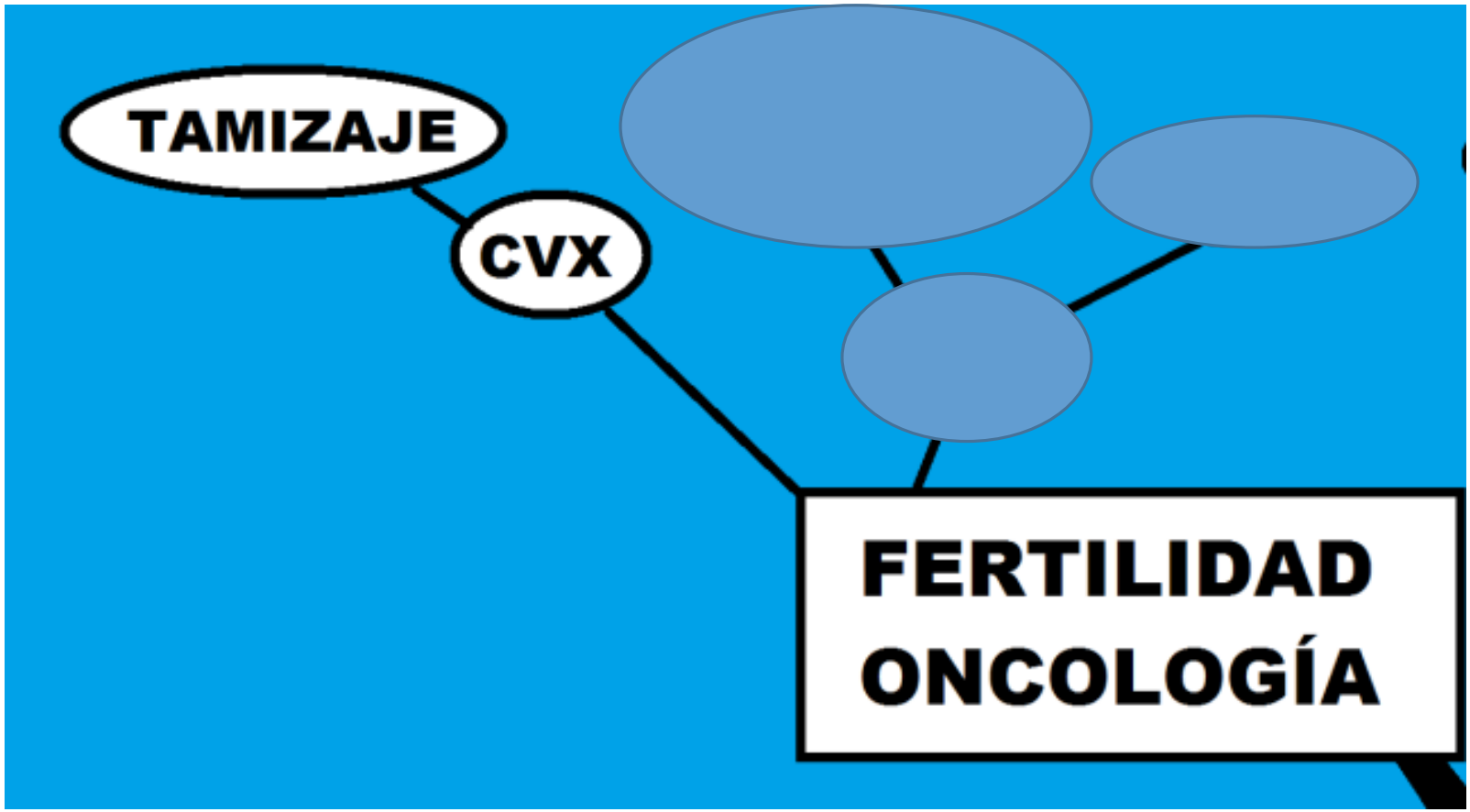
TAMIZAJE
CVX
FERTILIDAD
ONCOLOGÍA

FIGURA 16

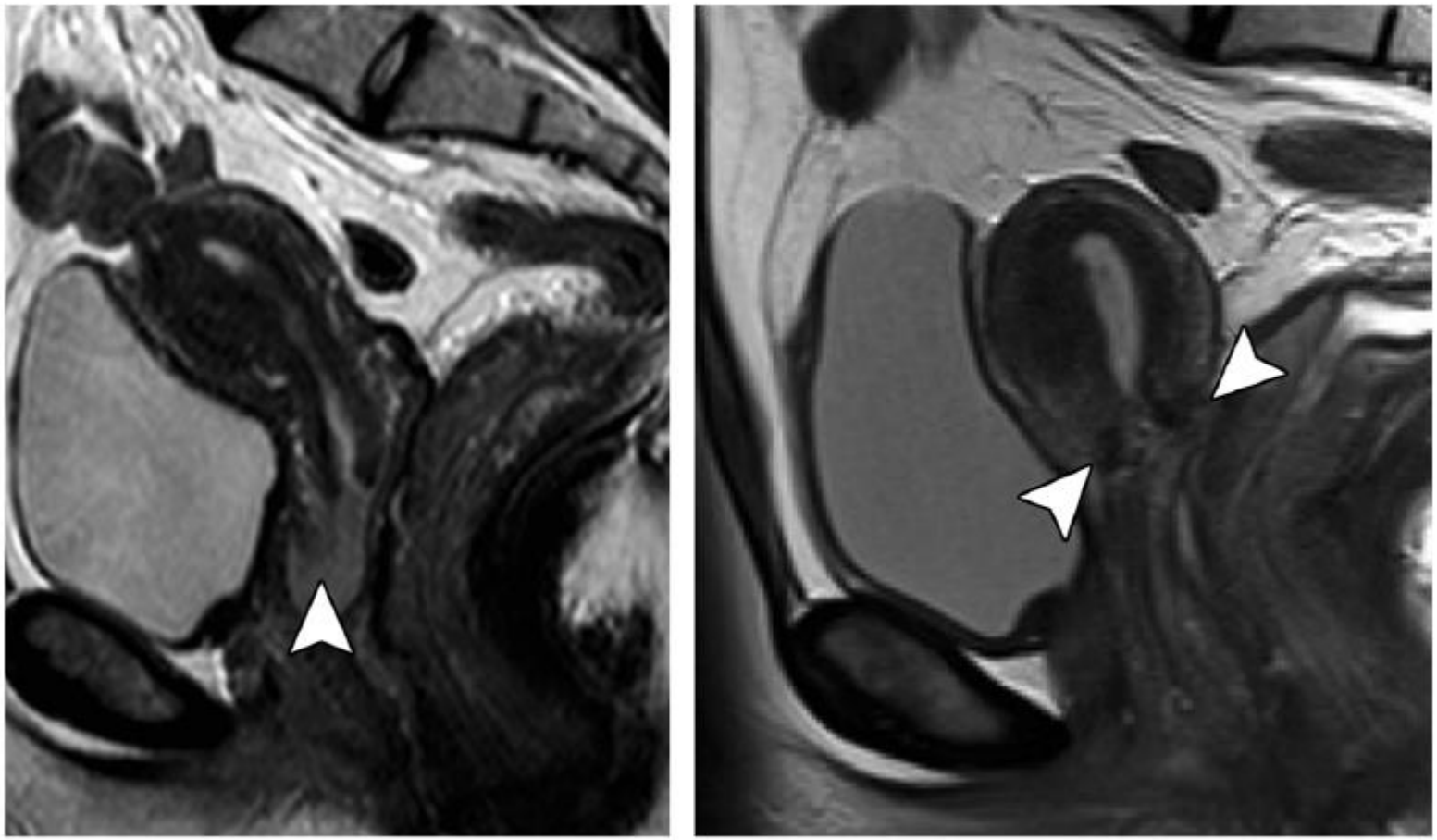

a. b.

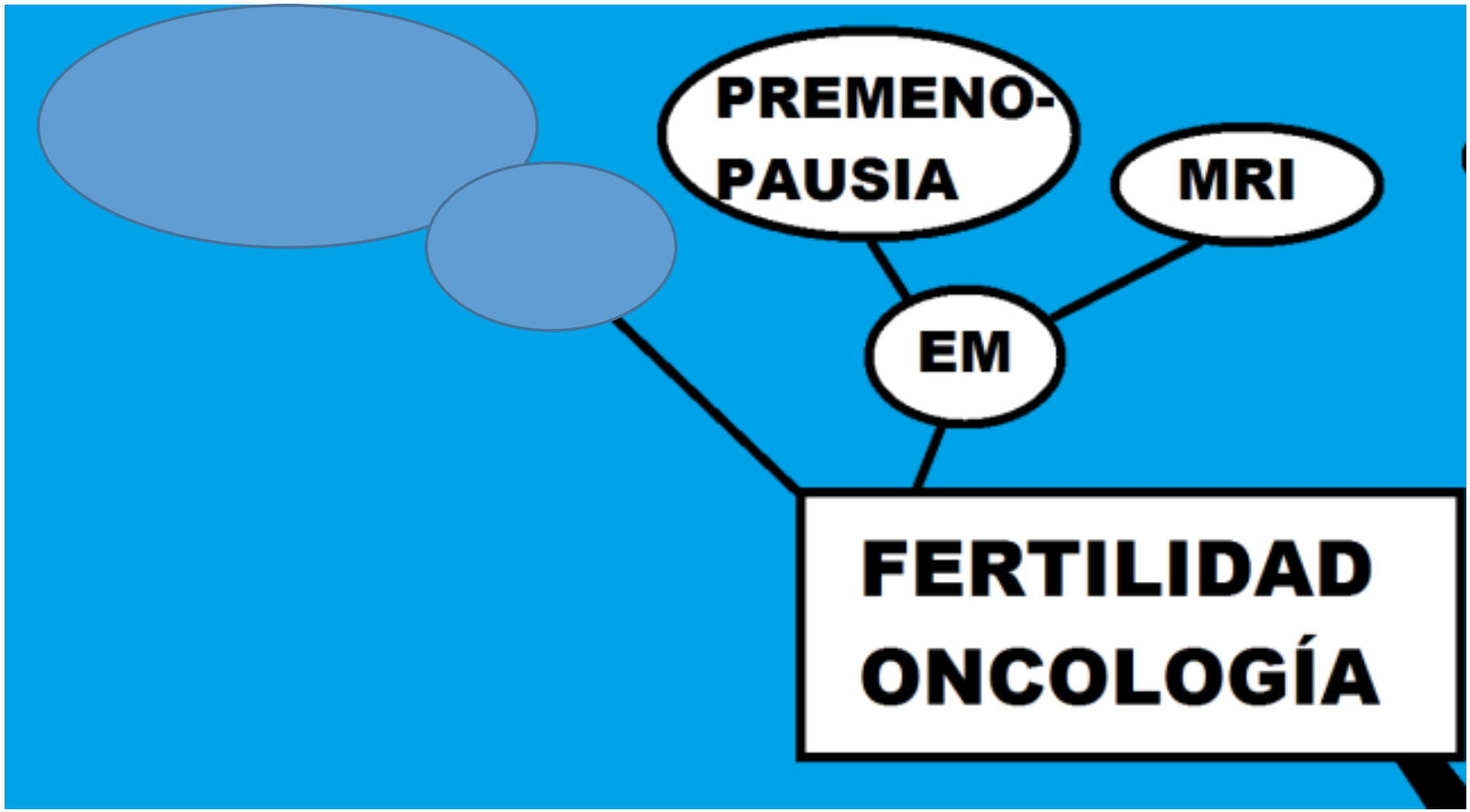
PREMENO-
PAUSIA
MRI
EM
FERTILIDAD
ONCOLOGÍA

FIGURA 17

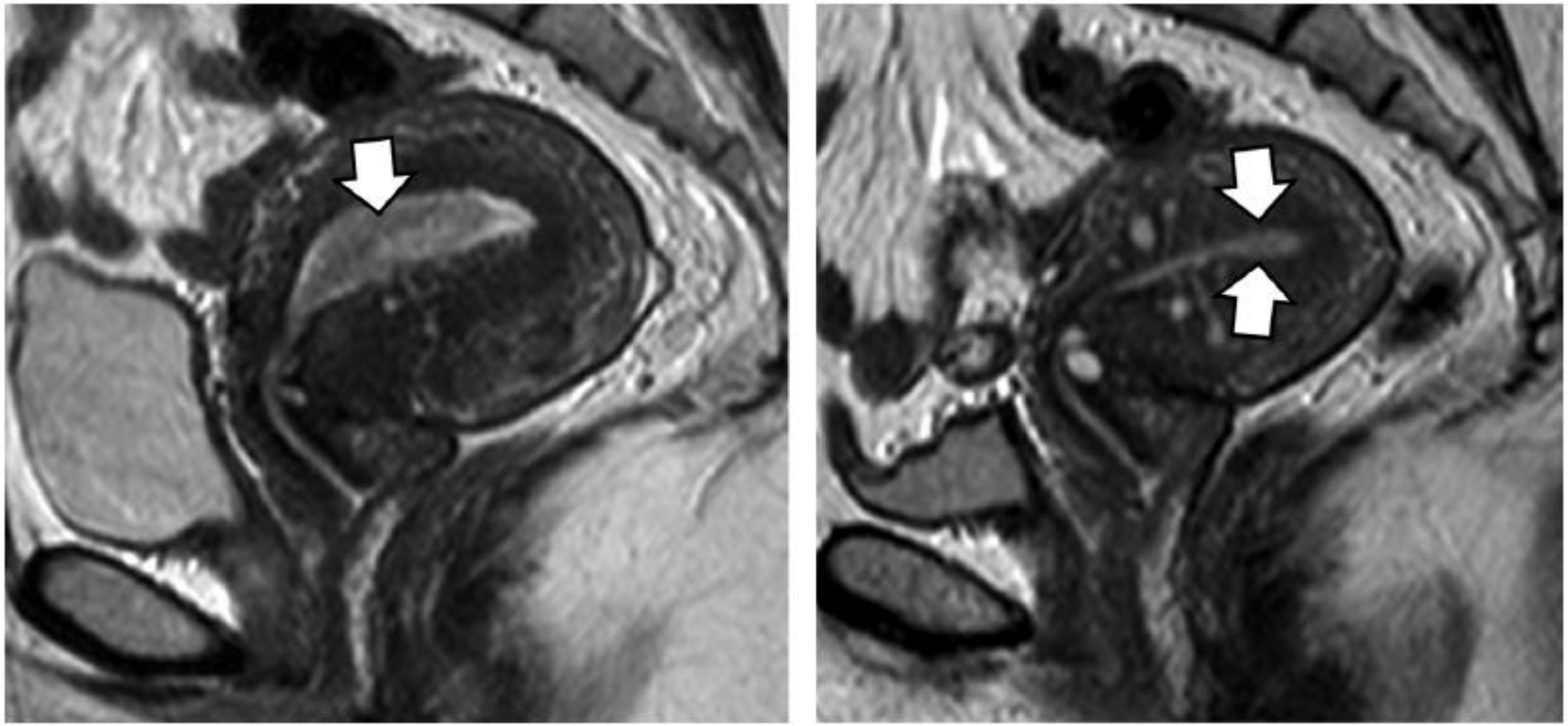

a. b.

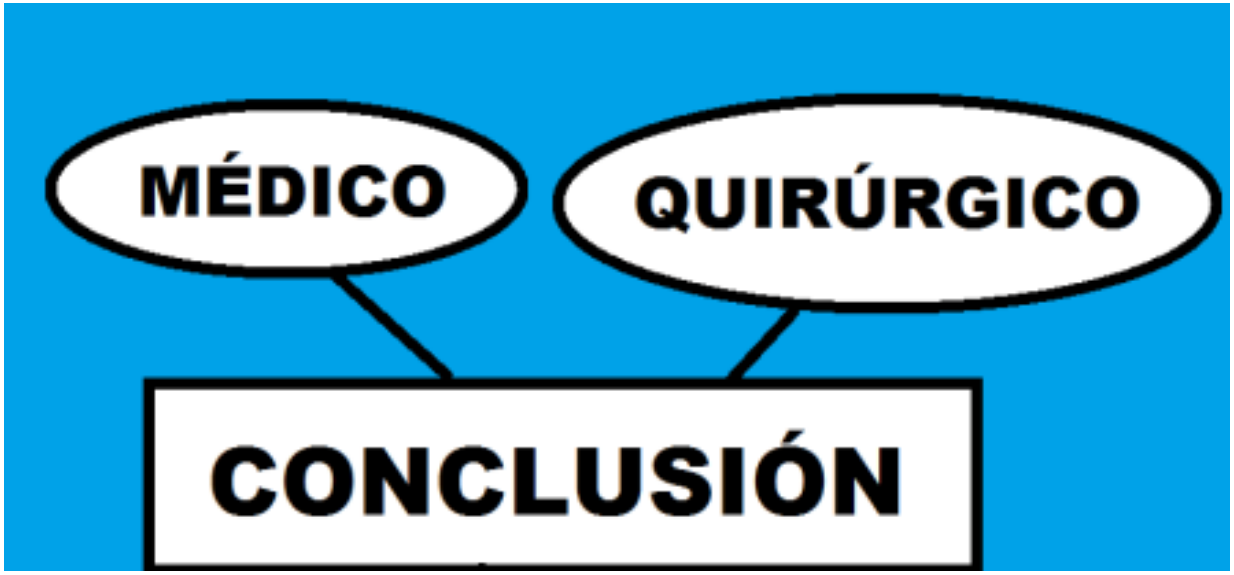
MÉDICO
QUIRÚRGICO
CONCLUSIÓN

SUBFERTILIDAD:
LO QUE NECESITA SABER EL RADIÓLOGO

INTRO
- SUBFERTILIDAD
- PREVALENCIA
- INICIO DE MATERNIDAD 1973 - 2013
- INFERTILIDAD > 1 AÑO
- ROL DXIM

CONCLUSIÓN
- MÉDICO
- QUIRÚRGICO

FERTILIDAD ONCOLOGÍA
- TAMIZAJE
- CVX
- PREMENO-PAUSIA
- MRI
- EM

CAUSAS
CONGÉNITAS
- CAVIDAD UTERINA DIVIDIDA
  - SEPTADO
  - BICORNE
  - DIDELFO
- MRKH
- UNICORNE

ADQUIRIDAS
- SIN
- OCL TUB
- SME ASH
- EM
- PÓLIPOS
- MIOMAS
- SOP

MODALIDADES DE IMÁGENES
- ECO
- HS - ECO CTE
- HSG
- MRI

Bibliografía

- Artículo principal

Vickramarajah S, Stewart V, Van Ree K, Hemingway AP, Crofton ME, Bharwani N. Subfertility: What that the Radiologist Needs to Know. RadioGraphics 2017;37:1587-1602. Accedido en junio 2020, disponible en: https://pubs.rsna.org/doi/full/10.1148/rg.2017170053

- Fuente externa de imágenes:
  - Renarajan R. Septate uterus with pregnancy.
  - Vadera S, Gaillard F. Bicornuate uterus
  - Sakinala K. Uterus didelphys
  - Publicados en línea en https://radiopaedia.org/

¡Gracias por su atención!