Radiology

ORIGINAL RESEARCH · GENITOURINARY IMAGING

Clear Cell Renal Cell Carcinoma Growth Correlates with Baseline Diffusion-weighted MRI in Von Hippel–Lindau Disease

Faraz Farhadi, BS • Moozhan Nikpanah, MD • Anna K. Paschall, BS • Ahmad Shafiei, MD • Ashkan Tadayoni, MD • Mark W. Ball, MD • W. Marston Linehan, MD • Elizabeth C. Jones, MD • Ashkan A. Malayeri, MD

From the Radiology and Imaging Sciences, NIH Clinical Center (F.F., M.N., A.K.P., A.S., A.T., E.C.J., A.A.M.), and Urologic Oncology Branch, Center for Cancer Research, National Cancer Institute (M.W.B., W.M.L.), National Institutes of Health, 10 Center Dr, Bethesda, MD 20814. Received May 3, 2019; revision requested June 3; revision received January 23, 2020; accepted February 4. **Address correspondence to** A.A.M. (e-mail: *ashkan.malayeri@nih.gov*).

Supported by the Intramural Research Program of the NIH Clinical Center.

Conflicts of interest are listed at the end of this article.

See also the editorial by Goh and Prezzi in this issue.

Radiology 2020; 295:583–590 • https://doi.org/10.1148/radiol.2020191016 • Content code: GU

Introducción

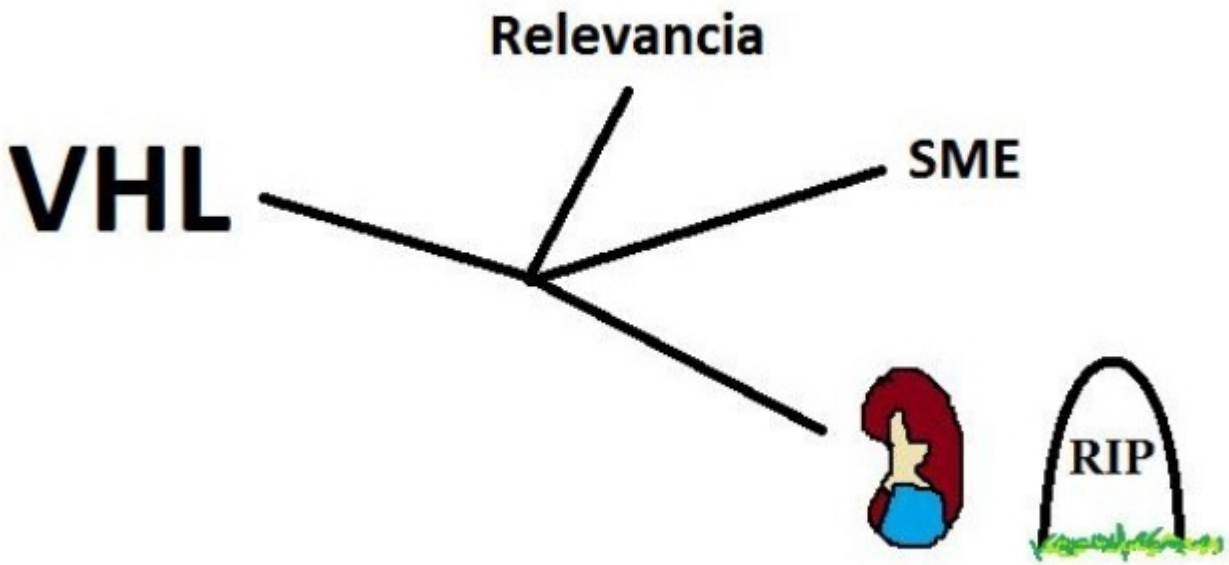

Introducción

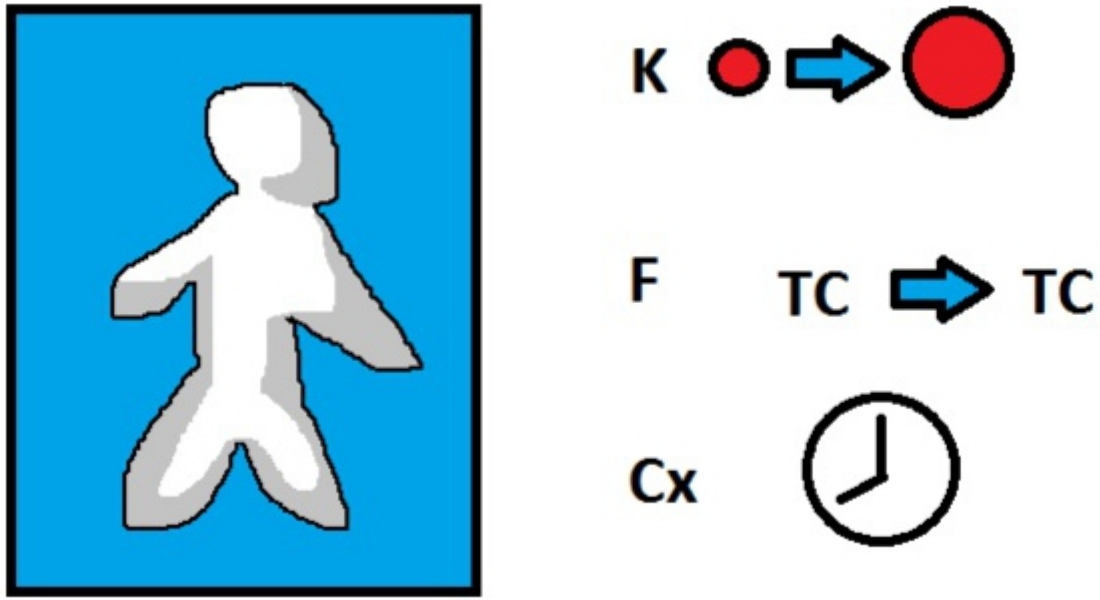

Introducción

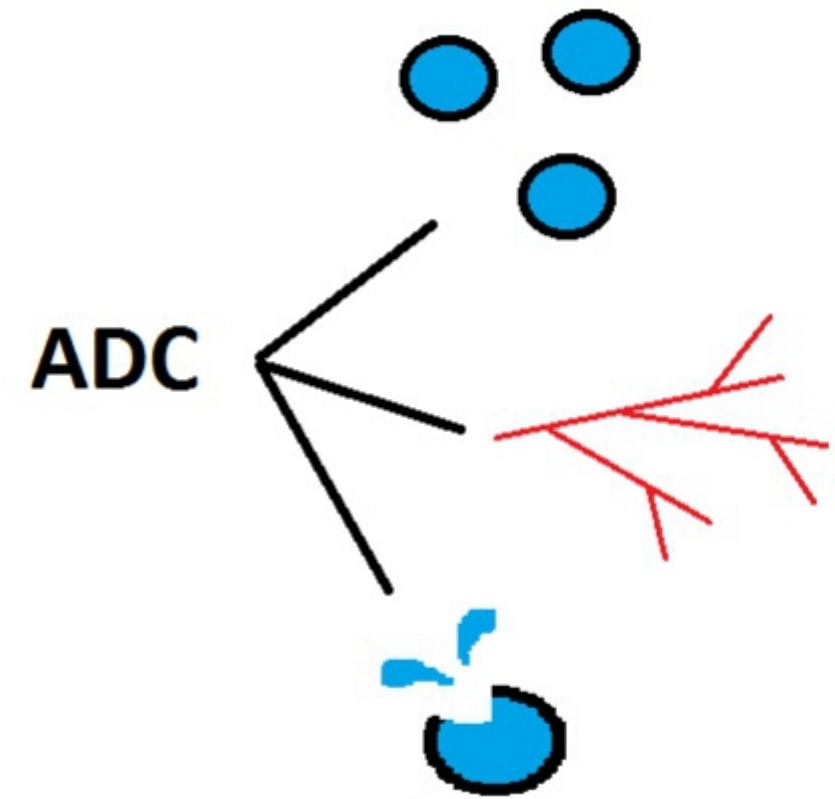

Introducción

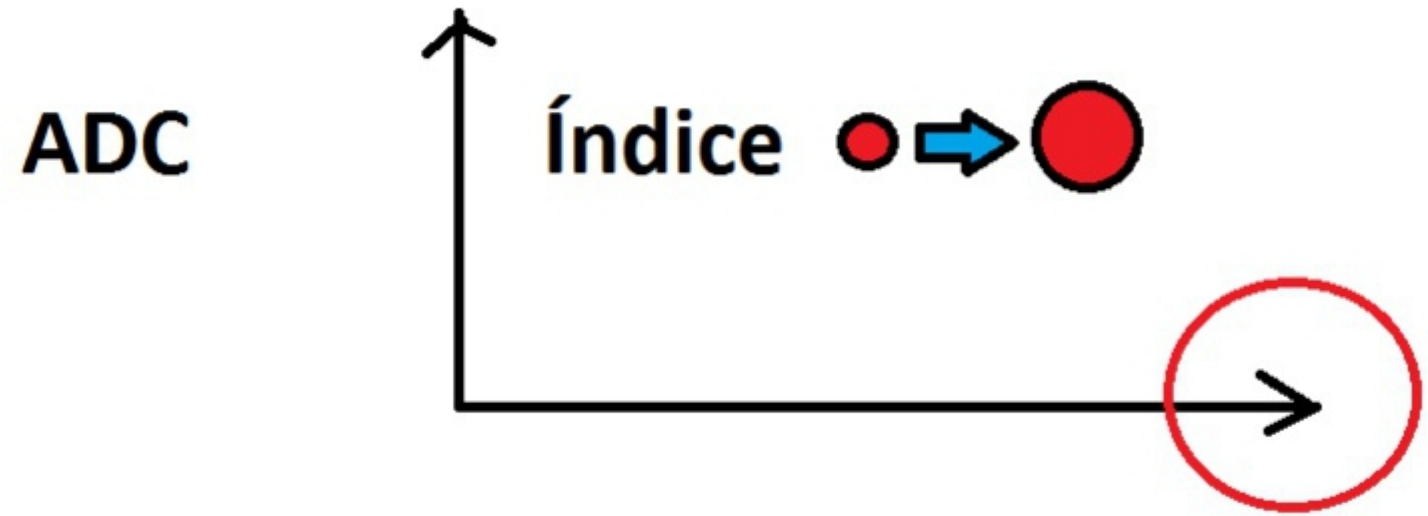

Materiales y Métodos

INCL	EXCL
VHL ccRCC	≥ 2 TC previo Cx
Histología	MRI ADC mismo día
	Mtts
	Artefactos
	QR
	T < 10 mm

Resultados

ADC

$\frac{1}{x}$ Índice

$\frac{x}{1}$ VDT

Resultados

ADC !

VDT > 1 añ

≤ 1 añ

ADC

S 67%
E 89%
Ex 81%

T

S 33%
E 84%
Ex 66%

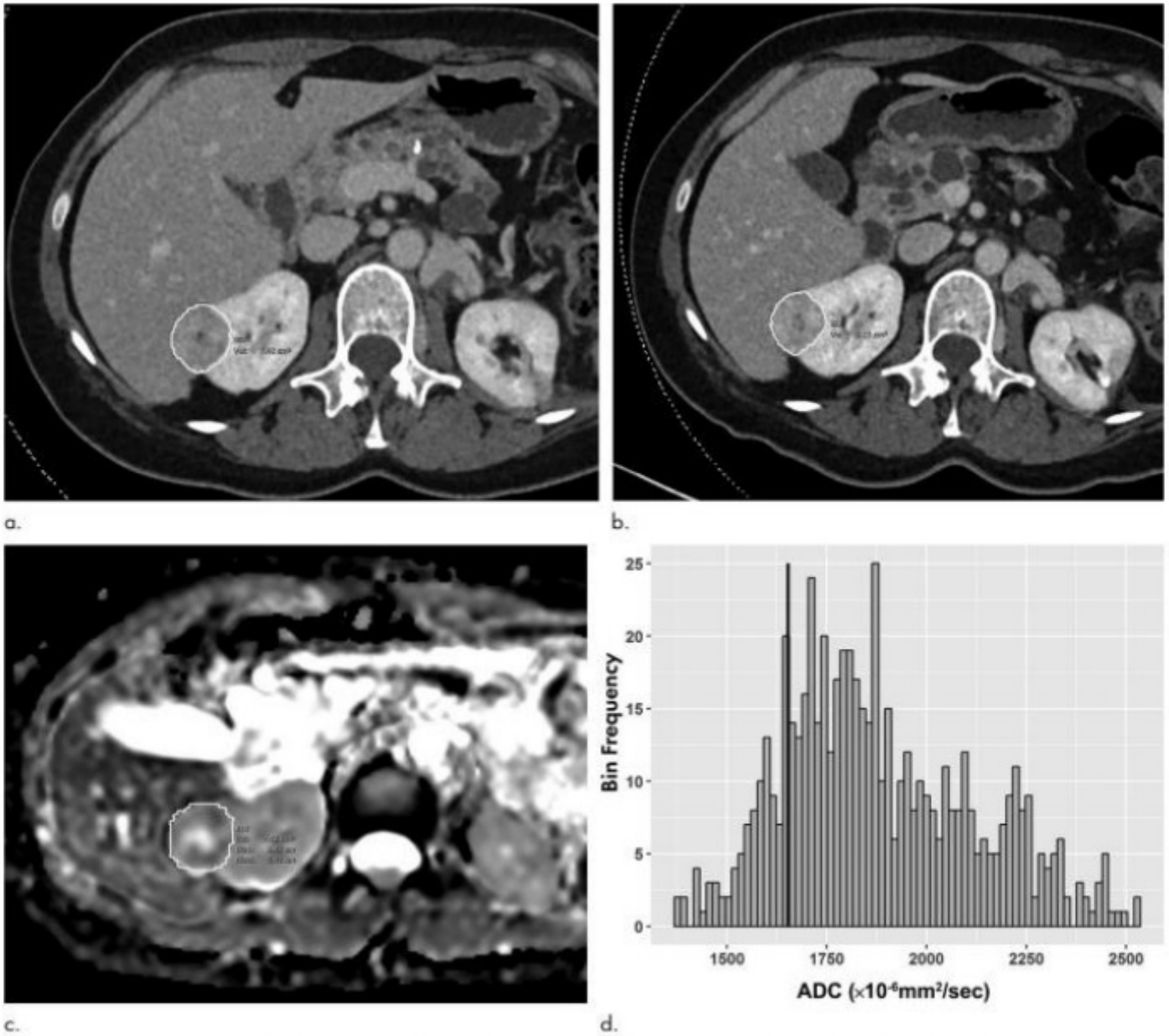

Figure 2: Images of clear cell renal cell carcinoma in a 55-year-old man with Von Hippel–Lindau syndrome. **(a, b)** Axial contrast material–enhanced nephrographic phase CT scans show the tumor was 7.4 cm^3 at baseline (**a**) and had grown to 9.1 cm^3 at 125 days (**b**). **(c)** Axial apparent diffusion coefficient (ADC) map of the tumor at baseline and **(d)** corresponding histogram percentile analysis.

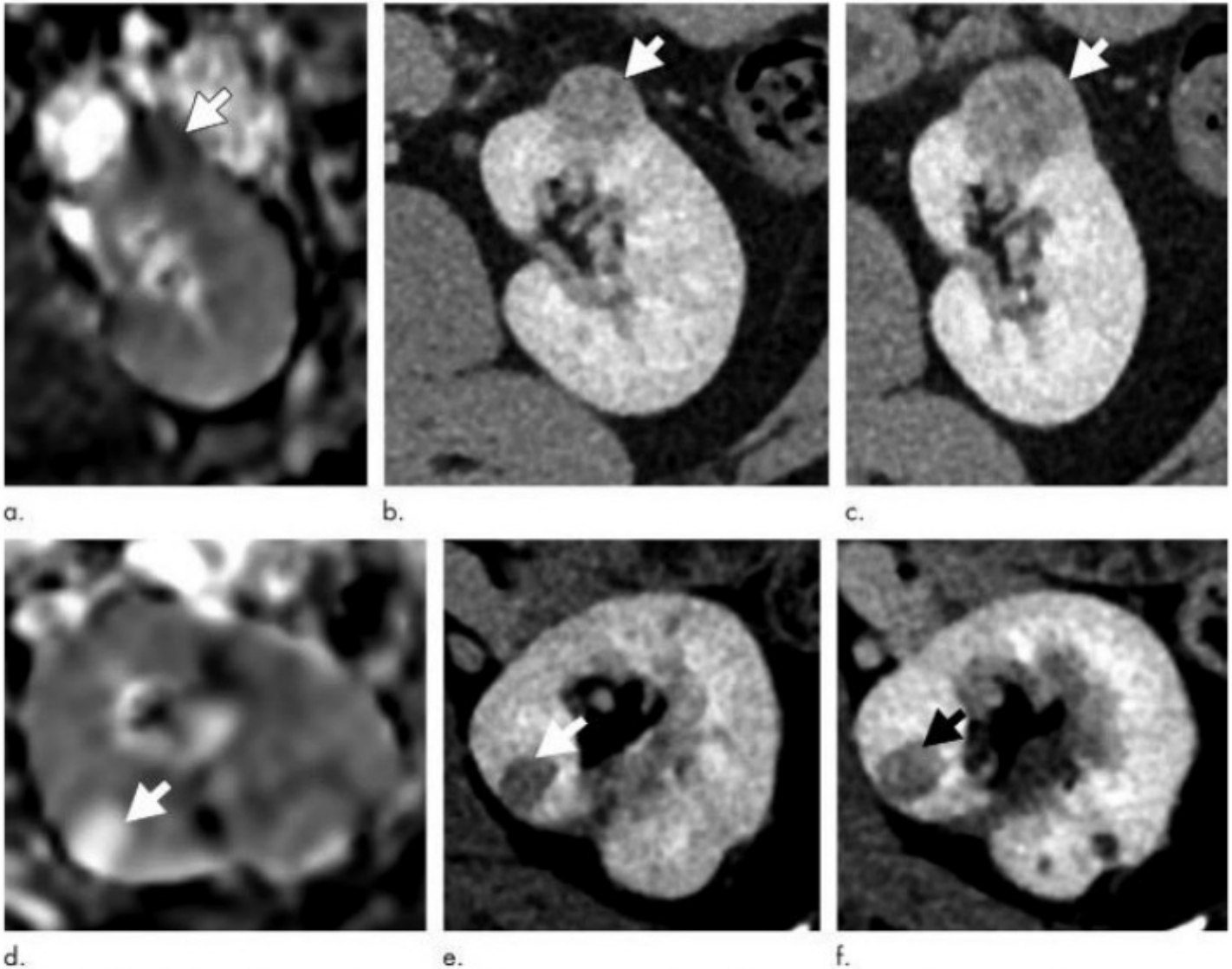

Figure 3: **(a–c)** Clear cell renal cell carcinoma (ccRCC) (arrow) in a 57-year-old man with Von Hippel–Lindau (VHL) disease that appears hypointense on **(a)** the baseline apparent diffusion coefficient (ADC) image (mean, 1536×10^{-6} mm^2/sec) and shows 8.9 cm^3 per year growth and 232-day doubling time between **(b)** baseline and **(c)** follow-up contrast-enhanced CT. **(d–f)** ccRCC (arrow) in a 61-year-old woman with VHL disease with a hyperintense appearance on **(d)** the baseline ADC image (mean, 2431×10^{-6} mm^2/sec) with 2.5-cm^3 per year growth and 1008-day doubling time between **(e)** baseline and **(f)** follow-up contrast-enhanced CT.

Discusión

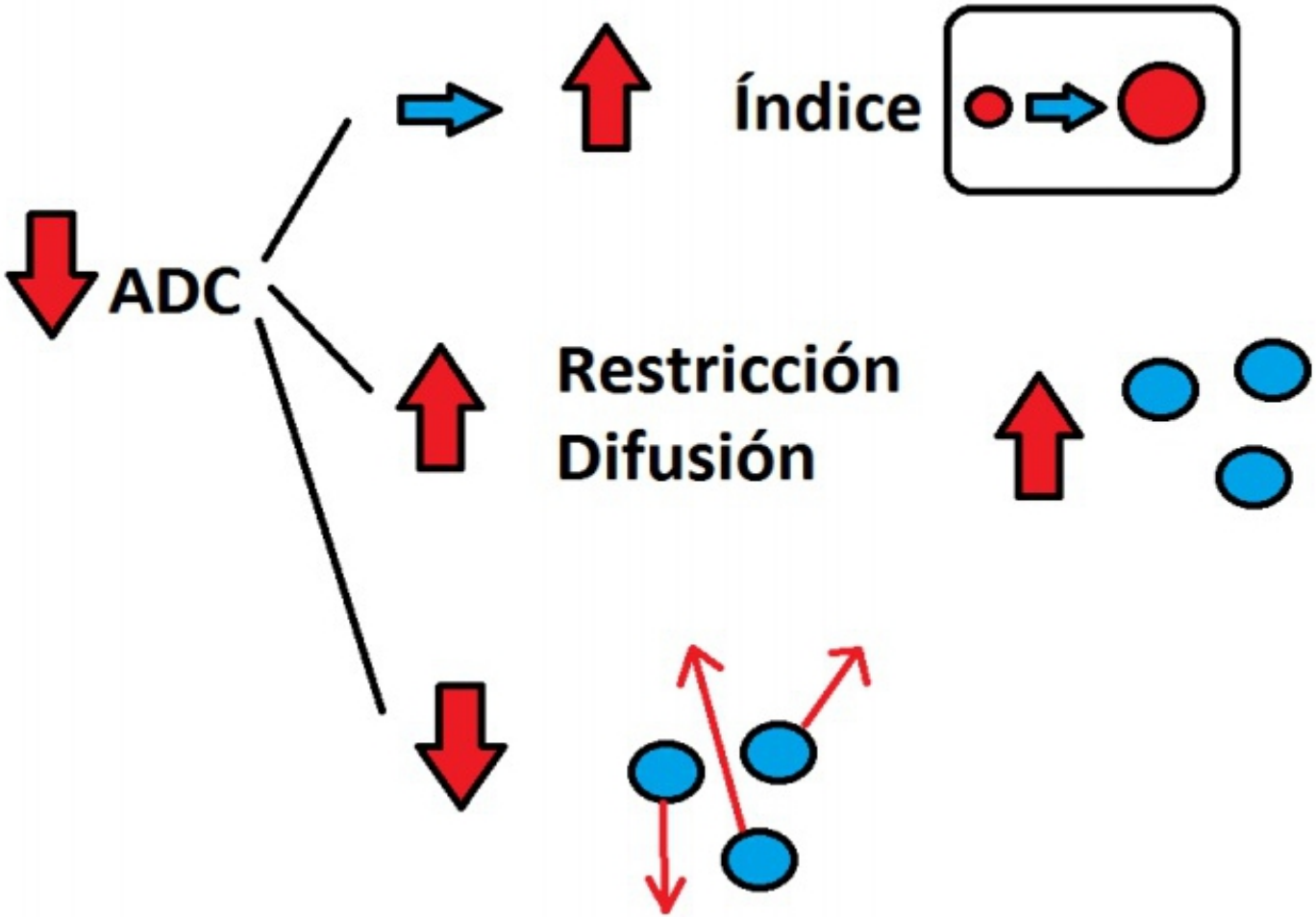

Discusión

Tamaño Tumoral

TEORÍA GOMPERTZIANO (CINÉTICA DEL CRECIMIENTO)

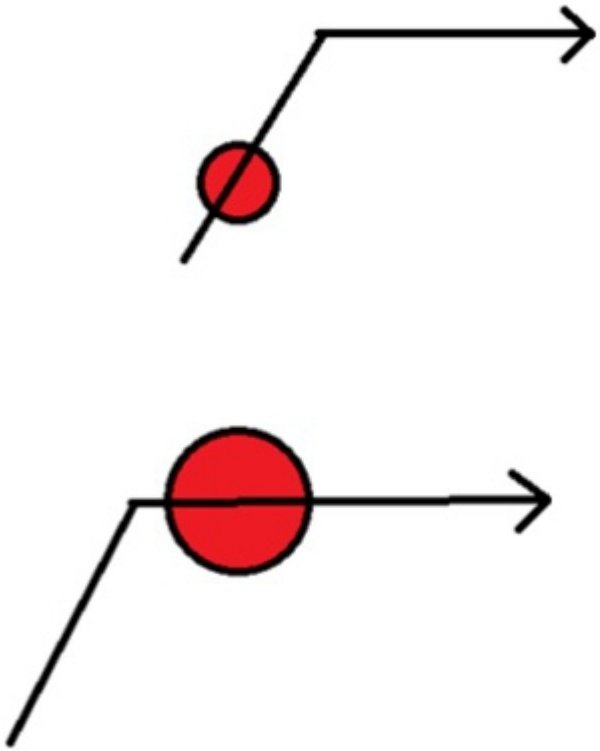

Discusión

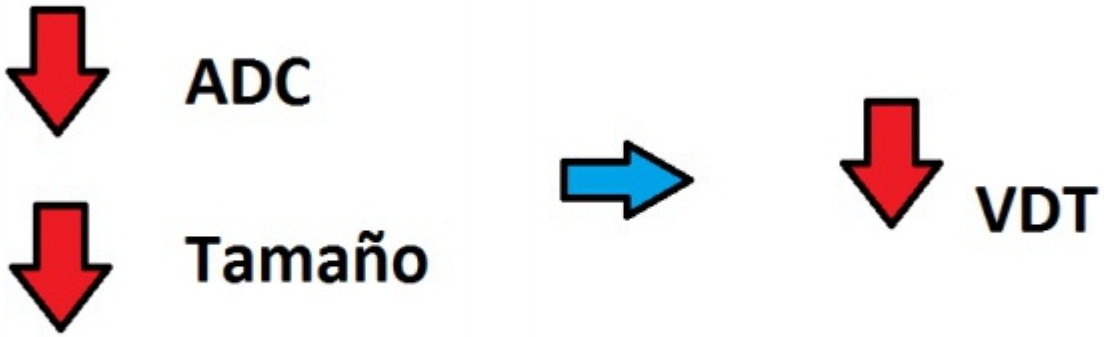

Radiology

REVIEWS AND COMMENTARY • EDITORIAL

Predicting Growth Kinetics in Hereditary Renal Cancer with Diffusion-weighted MRI

Vicky Goh, MD, FRCR • Davide Prezzi, FRCR

Dr Vicky Goh is a professor and the head of the Department of Cancer Imaging within the School of Biomedical Engineering and Imaging Sciences at King's College London. She is a deputy editor of *Radiology* and past president of the European Society of Oncologic Imaging. Her research focuses on functional and molecular imaging in oncology.

Dr Davide Prezzi is a uroradiologist and clinical senior lecturer at Guy's and St Thomas' Hospitals and King's College London, with research interests in renal cancer and functional MRI applied to body oncology.

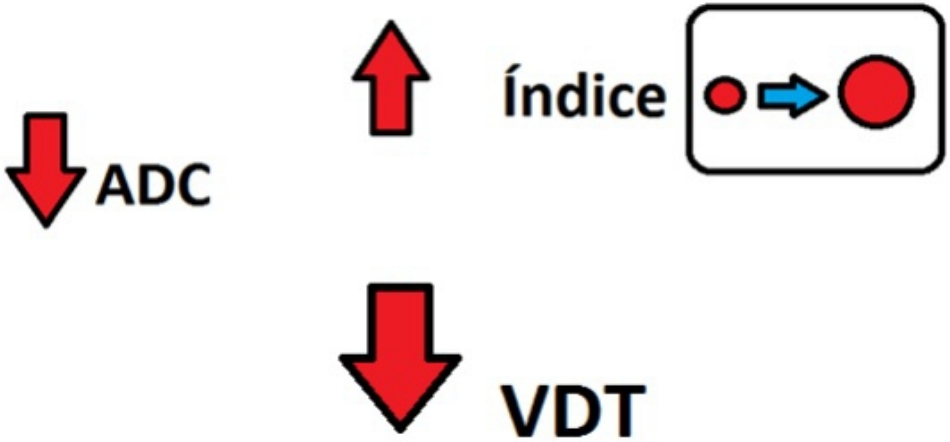
Índice
ADC
VDT

ADC 25%

+ correlación

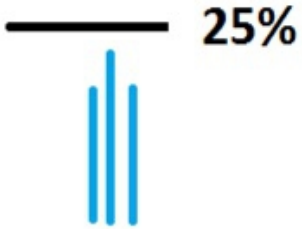

Dx tiempo único

⇩

Predicción cinética crecimiento

⇩

Nuevo rol ADC

¡GRACIAS!